

Research article

No effect of probiotics from the *Lactobacillus* and *Bifidobacterium* genera in the control of bacterial plaque in crab-eating fox *Cerdocyon thous* kept in human care

Sabrina F. Pires¹, Alcía G. Hippólito¹, Barbara S. Ferro¹, Ramiro das N. D. Neto², Fernanda M. Ar. M. Pereira¹, Priscylla T. C. G. Okamoto¹, Adriano S. Okamoto¹, Sheila C. Rahal², Carlos R. Teixeira² and Alessandra Melchert¹

¹Department of Veterinary Clinics, School of Veterinary Medicine and Animal Science, São Paulo State University - UNESP, Botucatu, São Paulo, 18618-681, Brazil.

²Department of Veterinary Surgery and Animal Reproduction, School of Veterinary Medicine and Animal Science, São Paulo State University - UNESP, Botucatu, São Paulo, 18618-681, Brazil.

Correspondence: Alessandra Melchert, e-mail; alessandra.melchert@unesp.br

Keywords: dentistry, probiotic, vulpid, wild canids

Article history:

Received: 25 Nov 2023

Accepted: 17 Sept 2024

Published online: Early online

Abstract

This study evaluated the effects of synergistic probiotic therapy on the formation of dental bacterial plaque in crab-eating foxes *Cerdocyon thous* in human care. Six crab-eating foxes with periodontal disease grades I and II were randomly divided into two groups of three animals. A total of 66 teeth were assessed per group. Group 1 received probiotics in powder form sprayed onto food once a day for 60 days. Group 2 received no probiotics but similar feeding as Group 1 subjects. The probiotic contained 1 billion organisms of *Lactobacillus reuteri*, *Lactobacillus salivarius*, *Lactobacillus brevis* and *Bifidobacterium bifidum*. Maxillary teeth were stained with 2% eosin and photographed before treatment and 60 days after cleaning. The images of maxillary and mandibular teeth were inspected using Photoshop software to obtain each tooth's total two-dimensional area and the bacterial plaque or dental calculus area. There was no significant difference in the global percentage of bacterial plaque and dental calculus between groups before and after treatment. The synergistic use of probiotics from the *Lactobacillus* and *Bifidobacterium* genera did not result in a statistically significant difference between groups. There were signs of probiotic adherence to some teeth.

Introduction

The crab-eating fox *Cerdocyon thous* is a medium-sized canid found in Venezuela, Colombia, Uruguay, Paraguay, Argentina and Brazil (Jorge and Jorge 2014). Although *C. thous* has been listed as a Least Concern species (Lucherini 2015), the Brazilian Institute of Environment and Renewable Natural Resources (IBAMA) considers *C. thous* vulnerable to extinction. Therefore, its ex-situ preservation is important, contributing to the genetic reserve and offering research opportunities that are impractical on free-living animals (Hutchins et al. 2003; Ruiz-Miranda et al. 2003). In addition, the increasing growth of agricultural and urban areas has changed the environment for crab-eating foxes, including food and water sources, forcing them to look

for other places to survive and increasing their mortality rate, especially in traffic accidents. Therefore, *C. thous* is widely kept in human care, at least across Latin American zoos.

The permanent dentition of *C. thous* consists of 42 teeth following the formula 2x (3/3 incisors, 1/1 canine, 4/4 premolars, 2/3 molars) (Wiggs and Lobprise 1997). Although *C. thous* is omnivorous, its diet varies seasonally. These animals are generalists and opportunists, eating wild fruit, insects, crustaceans, small vertebrates, fish and carrion (Gomes 2006; Pessutti et al. 2001). In the dry season, the diet of free-ranging *C. thous* includes small mammals (mainly rodents) and reptiles, while wild fruit and insects are the major food sources in the rainy season. As opportunists, it is likely that animals from different regions have different diets, adjusting their feeding

to environmental supply (Santos Júnior 2005). In wildlife centres, the food offered includes unpeeled, cut, cultivated fruit (such as banana, papaya, apple), chicken and commercial cat food. However, it is important to highlight that the chemical composition of wild fruits significantly differs from that of commercial foods, with wild fruits exhibiting higher fibre content and lower sugar levels (Taveira and Matos 2010).

Even though there are no reports of a higher propensity of crab-eating foxes to suffer from periodontal disease, this is probably the most common disease seen in small animal practice (Gorrel 2004) and most forms of periodontal disease seen in domestic animals can be found in exotic animals (Emily and Eisner 2021). However, *C. thous* kept in human care may present a higher incidence of periodontal disease compared to their wild counterparts. As in virtually any animal species, the food provided by humans may contain adequate nutritional levels but lacks the textural diversity required to maintain the health of teeth and gums (Fecchio et al. 2019; Rossi Junior 2007). This textural diversity plays a fundamental role because it provides for the animal's physiological needs regarding dental and gingival cleaning, maintenance of jaw muscle bulk and tone and maintenance of alveolar bone (Wiggs and Bloom 2003). A lack of textural diversity hence potentially increases the risk of poor oral health. Therefore, among the conditions affecting animals under human care, oral diseases deserve special consideration. Without adequate treatment, all oral conditions can have serious consequences from decreased appetite, weight loss, food loss during chewing, face swelling, oral fistulas, pain or discomfort, food selectivity, behavioural changes due to tooth loss and the development of systemic diseases. In addition, bacterial biofilm can contaminate and infect other organs, generating bacteraemia and sepsis, and destroy collagen, a critical protein for the body. This collagen destruction can lead to bone and cartilage deterioration, causing respiratory and heart disease (Wiggs and Lobprise 1997).

A study of 45 mixed-breed dogs established a significant correlation between the extent of periodontal disease and histopathological changes in the kidneys, myocardium (papillary muscle) and liver (DeBowes et al. 1996). Post-mortem analyses including periodontal evaluation, conventional necropsy and organ histology in 44 adult toy or miniature poodles revealed that for every square centimetre of periodontal disease, there was a 1.4 times greater likelihood of changes in the left atrioventricular valves, 1.2 times greater likelihood of liver disease and 1.4 times greater likelihood of kidney disease. These results showed an association between periodontal disease and the severity of internal conditions, indicating that periodontitis may contribute to the development of systemic diseases in domestic dogs (Pavlica et al. 2008).

Bacterial plaque is the primary etiological factor for periodontal disease. The plaque initially results in an inflammatory response in the protective periodontium and later in the supporting periodontium (Gorrel et al. 2013; Wiggs and Lobprise 1997). Common bacteria in periodontal disease include facultative aerobic, non-motile organisms, mainly *Streptococcus sanguinis* and *Actinomyces viscosus* (Gioso 2007; Gorrel et al. 2013). The bacterial plaque penetrates the tooth surface in 24 to 48 hours; next, the gingival sulcus becomes the ideal environment for the proliferation of anaerobic, gram-negative bacteria (Emily and Penman 1994) such as *Porphyromonas* spp., *Prevotella* spp., *Peptostreptococcus* spp. and *Fusobacterium* spp. (Harvey and Emily 1993). With no proper treatment, periodontal disease destroys the periodontium (Gioso 2007; Gorrel et al. 2013; Stepaniuk 2019). Periodontitis is a late manifestation of periodontal disease (Harvey 1998), in which bacterial plaque inserts into the gingival sulcus and triggers an immune response in the animal's oral cavity resulting in gingival retraction (Gioso 2007; Gorrel et al. 2013).

Gingival retraction leads to bone loss, resulting in instability and tooth mobility. During mastication, instable, mobile teeth are pushed against the remaining bone which undergoes exfoliation (Harvey 2005).

Conventional periodontal treatment with mechanical removal and disruption of the plaque biofilm is the most effective way for bacterial plaque control (Gioso 2007; Harvey and Emily 1993; Holmstrom 2019; Stepaniuk 2019). However, several studies have evaluated chemotherapeutic or natural agents to prevent or delay bacterial plaque growth on the tooth surface (Della Riccia et al. 2007; Gheisary et al. 2022; Saha et al. 2012; Song and Liu 2020; Teughels et al. 2013; Vives-Soler and Chimenos-Küstner 2020). The objectives of using probiotics in periodontal disease include promoting a balanced ecological environment by competitively excluding pathogenic bacteria (Meurman and Stamatova 2007; Song and Liu 2020). In the oral cavity, the probiotic-derived biofilm fills the spaces with accumulated pathogenic bacteria, reducing gingivitis, halitosis and carcinogenic bacteria that result in periodontal disease (Çağlar et al. 2005; Comelli et al. 2002; Nanavati et al. 2021). The potential role of probiotics in periodontal disease is to generate and balance the oral microbiota, decreasing the expression of inflammatory mediators and bacterial counts (Vives-Soler and Chimenos-Küstner 2020).

This study aimed to evaluate the effects of synergistic probiotic therapy on the formation of bacterial plaque on the teeth of crab-eating foxes kept in human care. The hypothesis was that the synergism of probiotics from *Lactobacillus reuteri*, *L. salivarius*, *L. brevis* and *Bifidobacterium bifidum* would reduce bacterial plaque with beneficial effects on the health of these animals.

Methods

Animal selection and dental evaluation

The Ethics Committee on Animal Use from FMVZ/UNESP and SISBIO approved this study under numbers 0173/2017 and 60130 respectively. The study included six crab-eating foxes with periodontal disease. The animals were under human care at a wild animal research centre (CEMPAS) in the city of Botucatu, São Paulo, Brazil, after being brought in by the environmental police. Their ages ranged from 1 to 6 years old and their average weight was 6 kg. The animals included five males and one female, all identified with an electronic microchip in the dorsal cervical region.

The animals were fed twice a day and their diet (as fed) consisted of 100 grams of animal material (chicken breast, neck, heart, minced meat, adult dog food) and 25 grams of cultivated fruit (banana, apple, mango, melon, guava and/or papaya). Water was offered for ad libitum consumption throughout the project. During the study period, the animals remained in the same enclosure with cemented floor and access to a controlled vegetation area without any other factors potentially impacting the results.

After 8 hours of food and water fasting, the animals were restrained with a net followed by intramuscular administration of ketamine hydrochloride (8 mg/kg) and midazolam hydrochloride (0.5 mg/kg) for sedation. After 20 minutes, general anaesthesia was induced with propofol (5mg/kg, intravenous route) and maintained with isoflurane under intubation. Under general anaesthesia, the animals underwent a dental examination to determine the degree of periodontal disease per the American Veterinary Dental College (Stepaniuk 2019). During the procedure, the animals received lactated Ringer's solution intravenously. The crab-eating foxes were positioned in lateral recumbency. The dental evaluation always started on the left side and used a periodontal probe. The assessed teeth included the maxillary third incisor, canine, first, second, third and fourth premolars, and the

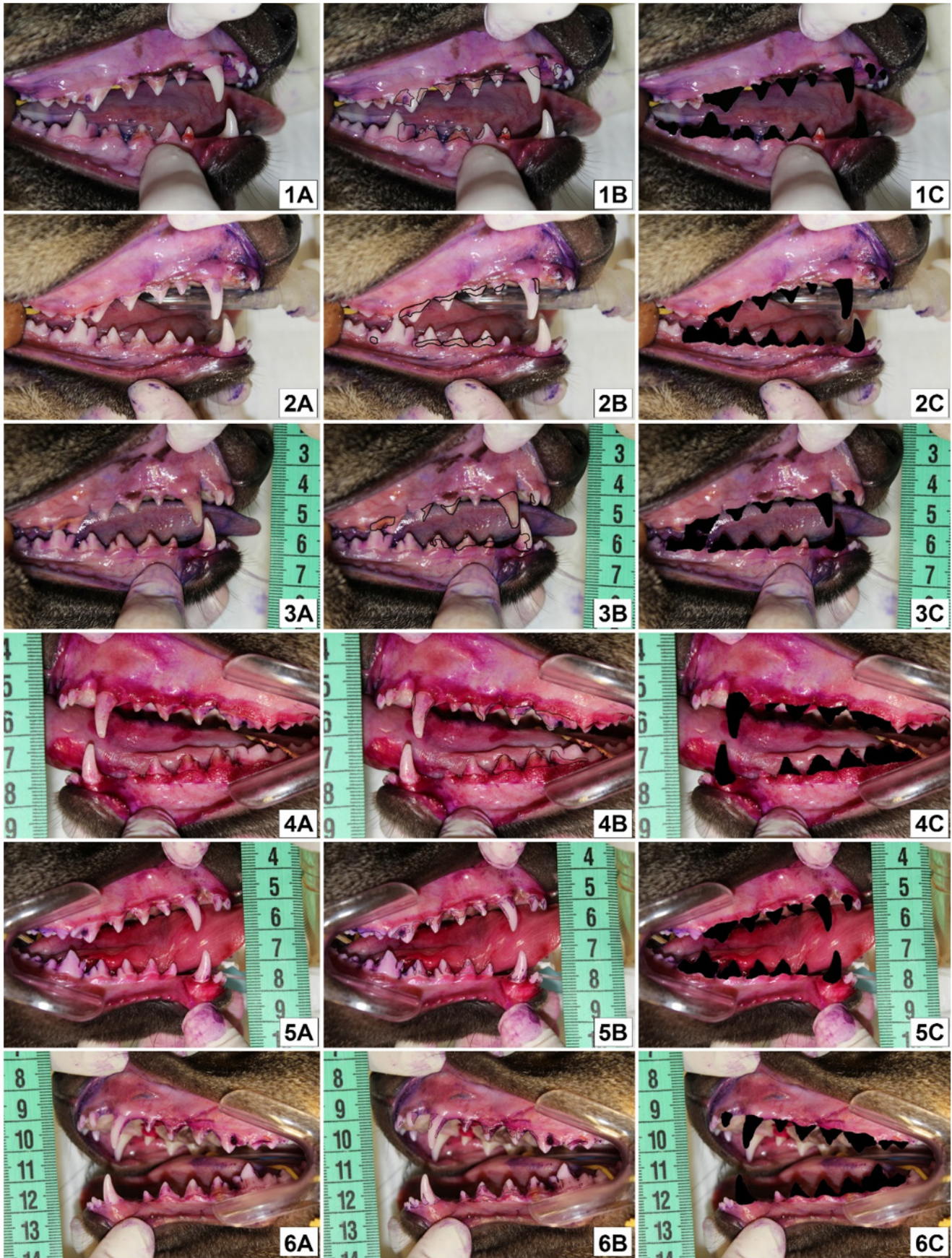

Figure 1. Illustration of the oral cavity of crab-eating foxes before treatment with probiotics. A = Areas stained with 2% aqueous eosin solution on the buccal surfaces of the teeth of the maxilla and mandible. B = Black staining of bacterial plaque areas using Photoshop. C = Black staining of the total tooth teeth evaluated using Photoshop.

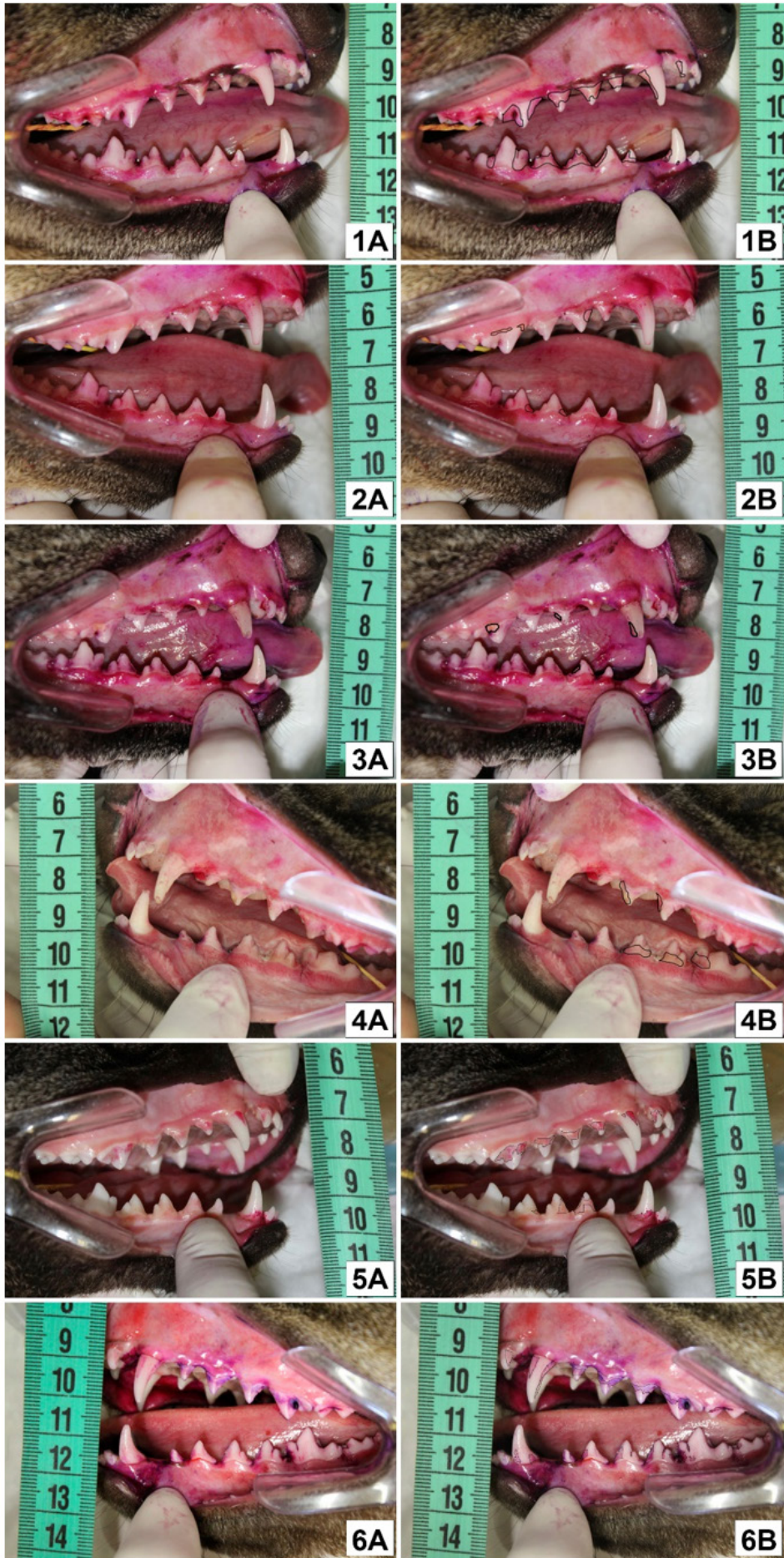

Figure 2. Illustration of three crab-eating foxes that received probiotics (1,2,3) and three crab-eating foxes that did not receive probiotics (4,5,6). A = Areas stained with 2% aqueous eosin solution on the buccal aspect of maxillary and mandibular teeth. B = Black staining of bacterial plaque areas using Photoshop.

mandibular canine, second, third and fourth premolars and first molar. All changes were recorded in an odontogram developed for domestic dogs. For the odontogram, the assessment covered the teeth on both the left and right side of the oral cavity.

The maxillary and mandibular teeth were stained with 2% eosin (s 1 and 2) and one side of the oral cavity photographed with a stationary table camera (Canon, 2592×1728 resolution). The distance between the oral cavity and the camera was 10 cm. The camera was in macro-option using flash. Photograph analysis used the Photoshop Online® program which treated the digital images of the maxillary and mandibular teeth from the right and left side by placing a single colour at the bacterial plaque or total dental calculus area (Figures 1 and 2). Image J determined the measurements and treated the images. The percentages of bacterial plaque or dental calculus on the buccal surface of the teeth were calculated after measuring the total area of the teeth.

Groups

After dental evaluation, dental calculus in the tooth crown was removed using a dental ultrasound device (Dabi Atlante, Ribeirão Preto, Brazil, with a rotation of 32,000 hertz per second), followed by subgingival and supragingival scaling with a #14 Gracey curette. The tooth enamel was polished with a prophylactic paste and a rubber cup attached to the low-rotation pen. All animals had grade I and II periodontal disease. Next, the animals were randomly divided into two groups of three animals, totalling 66 teeth evaluated per group. Group 1 received the probiotic in powder form while Group 2 did not.

Group 1 received the probiotic sprinkled on chicken necks or hearts. The chicken was offered in a plastic tray once a day in the morning for 60 days. Then, feeding followed the routine protocol including fruits and premium commercial food for domestic dogs (Golden Formula—Adult Dogs/Chicken and Rice, Premier Pet Indústria e Comércio Ltda, Dourado, Brazil). Group 2 had the same

diet but no probiotics. Both groups received the same amount of food two times a day on the same schedule.

A compounding pharmacy laboratory (Artpharma, Jundiaí, SP, Brazil) prepared the probiotic as a bacon-flavoured powder, producing 60 envelopes for each animal. Each envelope contained in total 1 billion of equal amounts of *Lactobacillus reuteri*, *L. salivarius*, *L. brevis* and *Bifidobacterium bifidum*.

At the end of the 60-day probiotic treatment, the animals were anaesthetised again following the previously described protocol. Maxillary and mandibular teeth from both groups were stained with 2% eosin and the photographs were repeated (Figure 2).

Statistical analysis

Initially, the percentages of bacterial plaques before and after treatment in Groups 1 and 2 were analysed using the Shapiro-Wilk normality test. Since the distribution was not normal, the Mann-Whitney U-test compared the percentages between Groups 1 and 2.

Comparisons considered each type of tooth for each group and the same teeth between groups after 60 days of treatment. Data underwent the Shapiro-Wilk normality test and the Bartlett test to verify variances between groups. The Kruskal-Wallis test compared the upper and lower teeth from Groups 1 and 2. The Mann-Whitney U-test compared individual teeth between Group 1 and Group 2. The statistical analysis used software (GraphPad Prism, Version 8.4.2) considering a significance level of $P < 0.05$.

Results

At the first assessment there was no statistically significant difference in the overall percentage of bacterial plaque between the groups before dental cleaning and probiotic administration ($P = 0.20$) (Figure 3A) or after dental cleaning at day 60 of evaluation ($P = 0.21$) (Figure 3B).

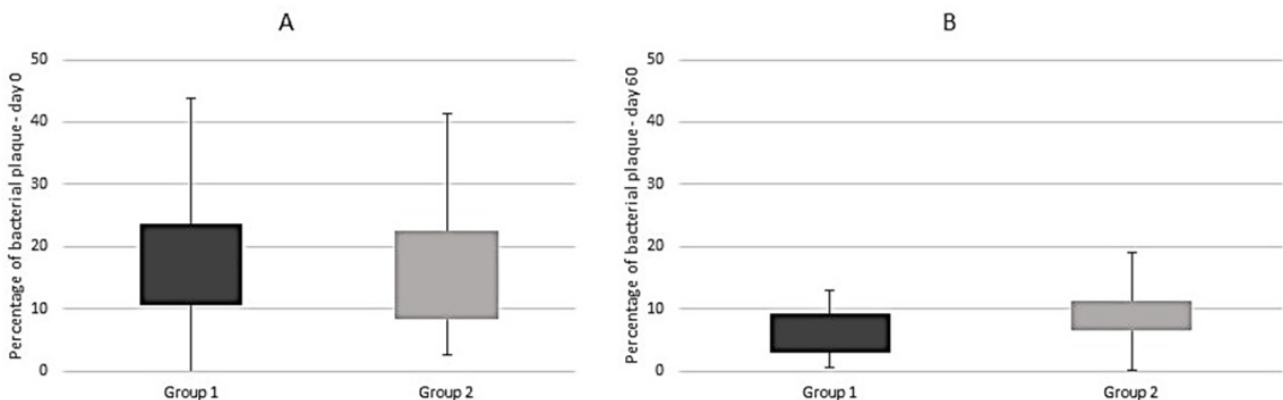


Figure 3. Boxplot representing the percentage of bacterial plaque in groups 1 (with probiotic treatment) and 2 (without probiotic treatment). (A) At the beginning of treatment, before dental cleaning. (B) At the end of the treatment – day 60, after dental cleaning for groups 1 and 2 and administration of 60 days of probiotic for group 1. There were no significant differences.

Figure 4 shows the percentage of bacterial plaque within Group 1 at day 60 of treatment. There were several significant differences between tooth positions, such as a significantly higher percentage of plaque in the maxillary fourth premolar teeth compared with first premolar teeth ($P=0.004$) and the third incisor teeth ($P=0.02$) and a higher percentage of plaque on the canine teeth compared to the first premolar teeth ($P=0.01$) (Figure 4A). Figure 4B shows statistical differences regarding the percentage of bacterial plaque in the mandibular teeth, where only the first molar teeth showed a higher percentage of plaque compared to the second premolar teeth ($P=0.004$).

Figure 5 shows the percentage of bacterial plaque within Group 2 at day 60 of treatment. Figure 5A reveals statistical differences in the percentage of bacterial plaque in maxillary teeth i.e. the fourth premolar presented a significantly higher percentage of plaque compared with the third incisor ($P=0.02$) and the first premolar teeth ($P=0.04$). Figure 5B reveals no statistical differences in the percentage of bacterial plaque in mandibular teeth ($P=0.09$).

Additionally, when comparing the maxillary and mandibular teeth between Groups 1 and 2, no significant differences were observed for any of the teeth.

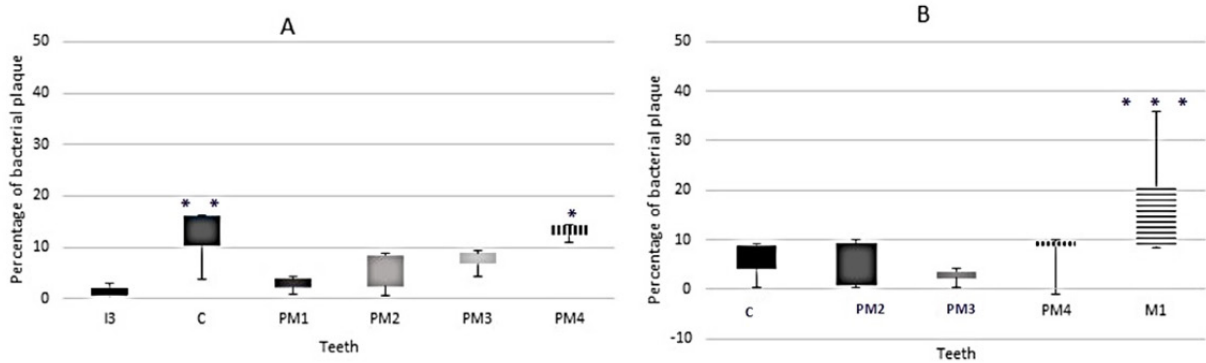


Figure 4. Boxplots comparing the percentage of bacterial plaque in group 1 (with probiotic treatment) after 60 days. (A) Maxillary teeth. (B) Mandibular teeth. I3, Third incisor; C, canine; PM1, first premolar; PM2, second premolar; PM3, third premolar; PM4, fourth premolar; M1, first molar. Significant differences within the maxilla or the mandible are indicated by asterisks (* $P<0.05$ x I3 and PM1; ** $P<0.05$ x PM1; *** $P<0.01$ x PM2).

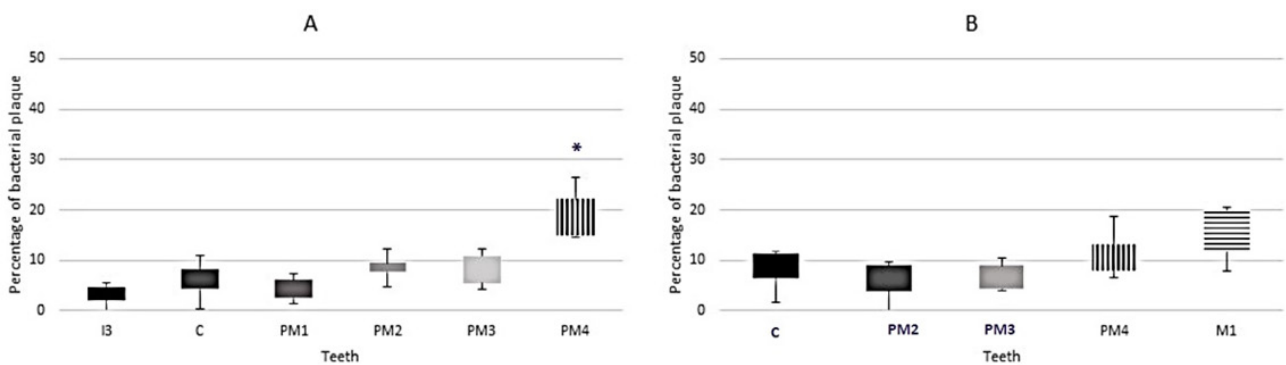


Figure 5. Boxplots comparing the percentage of bacterial plaque in group 2 (without probiotic treatment) after 60 days. (A) Maxillary teeth. (B) Mandibular teeth. I3, Third incisor; C, canine; PM1, first premolar; PM2, second premolar; PM3, third premolar; PM4, fourth premolar; M1, first molar. Significant differences within the maxilla or the mandible are indicated by asterisks (* $P<0.05$ x I3 and PM1).

Discussion

This study rejects the hypothesis of synergistic probiotic therapy effects on plaque formation. Crab-eating foxes were chosen for assessment because of the cranial and dental morphological similarity between domestic dogs and wild canids (Elbroch 2006; Reis et al. 2006), facilitating result interpretation. Additionally, *C. thous* are common in wild animal screening centres.

All crab-eating foxes in this study had periodontal disease in the initial evaluation. Periodontal disease due to bacterial plaque ranged from grade I to II per the American Veterinary Dental College classification (Stepaniuk 2019). In a study with *Procyon cancrivorus syncrania*, the most prevalent oral condition was periodontal disease, with an 85.39% incidence. This was the highest incidence of periodontal diseases in animals under human care, potentially due to changes in diet and eating habits (Bianchi et al. 2013). This demonstrates the significance of dental evaluation to improve the quality of life of animals under human care and to include treatments to minimise periodontal disease occurrence (Fecchio et al. 2019).

This study used *Lactobacillus reuteri*, *L. salivarius*, *L. brevis* and *Bifidobacterium bifidum* in powder form. The selection of these organisms occurred because of the beneficial effect of *Lactobacillus* as an antagonist, inhibiting periodontal pathogens such as *Aggregatibacter actinomycetemcomitans*, *Prevotella intermedia* and *Porphyromonas gingivalis*. *Lactobacilli* produce lactic acid (lowering the pH of the oral cavity) and release hydrogen peroxide, resulting in the maintenance and balance of oral microbiota (Karpiński and Szkaradkiewicz 2013). *Bifidobacterium* has a synergistic effect on significantly reducing the salivary counts of *Streptococcus mutans* by inhibiting the adherence of this pathogenic bacteria. In addition, it has a selective activity against *S. mutans* (Jindal et al. 2012; Marsh 2006).

No significant statistical differences were observed in the global teeth comparison between Groups 1 and 2 after 60 days of probiotic therapy. Some factors may have contributed to this result. The first factor refers to the administration form of the probiotic. As *C. thous* is a wild animal, the probiotic could not be directly applied to these animals' oral cavities unlike in the study of the anti-inflammatory effect of *Lactobacillus brevis* in human patients with periodontitis (Della Riccia et al. 2007). It is also worth mentioning that several authors have shown the impact of *Lactobacillus* and *Bifidobacterium* probiotics alone (Jindal et al. 2012; Marsh 2006; Nadkerny et al. 2015; Saha et al. 2012; Song and Liu 2020; Teughels et al. 2013) not in combination as in this study. Mäkinen et al. (2019) evaluated the effectiveness of an oral probiotic administered to 13 domestic dogs (Pomeranian and Peruvian hairless breeds) aged 1.5 to 9 years old with mild to severe periodontal disease and nine exotic cats aged 6 months to 2.5 years old with mild to severe periodontal disease. This probiotic consisted of *Streptococcus thermophilus* (SP4), *Lactobacillus plantarum* (14D) and *Lactobacillus rhamnosus* (SP1) in an amount of 109 colony-forming units per organism. Probiotic administration occurred in powder form over dry food for 30 to 40 days. Cats presented a significant reduction in the total percentage of the relative abundance of *Porphyromonas gingivalis* from 0.9% to 0.5% and a non-significant decrease in *Fusobacterium* sp. from 2.0% to 0.9%. In contrast, dogs had a significant reduction in the percentage of *Fusobacterium* sp. and a non-significant decrease in *P. gingivalis*. These authors suggested that their probiotics prevented the growth of infectious bacteria that are known to cause infections in pets' mouths. Compared with the current study, Mäkinen et al. (2019) used different bacteria and a shorter treatment period but the number of organisms and the administration route were similar. Even though there were non-statistically different results, a trend for plaque accumulation on

the maxillary canine and fourth premolar and mandibular first molar teeth compared to the other teeth was observed.

The mandibular first molar and the maxillary fourth premolar had a greater tendency to accumulate bacterial plaque. This higher tendency probably relates to tooth morphology and salivary duct outlets. In domestic dogs, the vestibular aspect of the maxillary fourth premolar and the cervical third of the canines present more plaque accumulation (Kowalesky 2005).

It is recommended that all rehabilitation centres and zoos should try to provide food closer to or equal to what these animals consume in the wild, with a diverse texture. This could include offering fruits whole and providing raw meat with bones, skin and hair to help keep the oral cavity clean and reduce bacterial plaque accumulation. When a soft diet is used for captive wild felids, supplementing with bones can be an important adjunct in preventing plaque and calculus formation and in maintaining oral health (Haberstroh et al. 1984).

An obvious limitation of this study is the small sample size, reducing the statistical power. Further studies should include higher numbers of animals and potentially use probiotic agents in different combinations, alone or even from different species.

Conclusions

The synergistic use of probiotics of the *Lactobacillus* and *Bifidobacterium* genera did not generate a statistically significant difference between groups at the global teeth comparison.

References

- Bianchi M.A.F., Mayorga L.F.S.P., Castro A.P.A., Rossi Junior J.L. (2013) Study of the ante-mortem changes of the oral cavity of crab-eating raccoon (*Procyon cancrivorus*) free living and in captivity. *Brazilian Journal of Veterinary Research* 33(5): 651–661.
- Çaglar E., Kargul B., Tanboga I. (2005) Bacteriotherapy and probiotics' role on oral health. *Oral Diseases* 11(3): 131–137. Comelli E.M., Guggenheim B., Stingle F., Neeser J.R. (2002) Selection of dairy bacterial strains as probiotics for oral health. *European Journal of Oral Sciences* 110(3): 218–224. doi:10.1034/j.1600-0447.2002.21216.x
- DeBowes L.J., Mosier D., Logan E., Harvey C.E., Lowry S., Richardson D.C. (1996) Association of periodontal disease and histologic lesions in multiple organs from 45 dogs. *Journal of Veterinary Dentistry* 13(2): 57–60. doi:10.1177/089875649601300201
- Della Riccia D.N., Bizzini F., Perilli M.G., Polimeni A., Trinchieri V., Amicosante G., Cifone M.G. (2007) Anti-inflammatory effects of *Lactobacillus brevis* (CD2) on periodontal disease. *Oral Diseases* 13(4): 376–385. doi:10.1111/j.1601-0825.2006.01291.x
- Elbroch M. (ed.). (2006) *Animal Skulls: A Guide to North American Species*. Mechanicsburg, Pennsylvania: Stackpole Books.
- Emily P.P., Eisner E.R. (2021) *Zoo and Wild Animal Dentistry*. 1st ed. Hoboken, New Jersey: Wiley-Blackwell.
- Emily P., Penman S. (1994) *Handbook of Small Animal Dentistry*. 2nd ed. Oxford, UK: Pergamon.
- Fecchio R., Gioso M.A., Bannon K. (2019) Exotic animals oral and dental diseases. In: Lobprise H.B., Dodd J.R. (eds.). *Wiggs's Veterinary Dentistry: Principles and Practice*. Hoboken, New Jersey: Wiley Blackwell, 481–499.
- Gheisary Z., Mahmood R., Harri Shivanantham A., Liu J., Lieffers J.R.L., Papagerakis P., Papagerakis S. (2022) The clinical, microbiological, and immunological effects of probiotic supplementation on prevention and treatment of periodontal diseases: A systematic review and meta-analysis. *Nutrients* 14(5): 1036. doi:10.3390/nu14051036
- Gioso M.A. (2007) *Veterinary Dentistry for the Small Animal Clinician*. 2nd ed. São Paulo, Brazil: Manole.
- Gomes M.S. (2006) Carnívora – Canidae (lobo-guará, cachorro-do-mato, raposa-do-mato). In: Cubas Z.S., Silva J.C.R., Catão-Dias J.L. (eds.). *Tratado de Animais Selvagens: Medicina Veterinária*. 1st ed. São Paulo, Brazil: Roca, 492–504.
- Gorrel C. (2004) *Veterinary Dentistry for the General Practitioner*. 1st ed. London, UK: Saunders.
- Gorrel C., Andersson S., Verhaert L. (2013) Periodontal disease. In: Gorrel C., Andersson S., Verhaert L. (eds.). *Veterinary Dentistry for the General Practitioner*. Edinburgh, UK: Saunders Elsevier, 97–119.

- Haberstroh L.I., Ullrey D.E., Sikarski J.G., Richter N.A., Colmery B.H., Myers T.D. (1984) Diet and oral health in captive Amur tigers (*Panthera tigris altaica*). *Journal of Zoo Animal Medicine* 15(4): 142–146. doi:10.2307/20094710
- Harvey C.E., Emily P. (1993) *Small Animal Dentistry*. Ann Arbor, Michigan: Mosby.
- Harvey C.E. (1998) Periodontal disease in dogs. Etiopathogenesis, prevalence, and significance. *Veterinary Clinics of North America: Small Animal Practice* 28(5): 1111–1128. doi:10.1016/S0195-5616(98)50105-2
- Harvey C.E. (2005) Management of periodontal disease: Understanding the options. *Veterinary Clinics of North America: Small Animal Practice* 35(4): 819–836. doi:10.1016/j.cvsm.2005.03.002
- Holmstrom S.E. (2019) *Veterinary Dentistry. The Team's Approach*. St. Louis, Missouri: Elsevier.
- Hutchins M., Smith B., Allard R. (2003) In defense of zoos and aquariums: The ethical basis for keeping wild animals in captivity. *Journal of the American Veterinary Medical Association* 223(7): 958–966.
- Jindal G., Pandey R.K., Singh R.K., Pandey N. (2012) Can early exposure to probiotics in children prevent dental caries? The current perspective. *Journal of Oral Biology and Craniofacial Research* 2(2): 110–115. doi:10.1016/j.jobcr.2012.05.001
- Jorge R.S.P., Jorge M.L.S.P. (2014) Carnivora – Canidae. In: Cubas Z.S., Silva J.C.R., Catão-Dias J.L. (eds.). *Tratado de Animais Selvagens – Medicina Veterinária*. São Paulo, Brazil: Roca, 764–778.
- Karpiński T.M., Szkaradkiewicz A.K. (2013) Microbiology of dental caries. *Journal of Biology and Earth Sciences* 3(1): M21–M24.
- Kowalesky J. (2005) Tooth Anatomy of the Dog (*Canis familiaris*) and the Cat (*Felis catus*). Surgery Considerations. São Paulo, Brazil: MSc Thesis, Faculty of Veterinary Medicine and Animal Science, University of São Paulo.
- Lucherini M. (2015) *Cerdocyon thous*. The IUCN Red List of Threatened Species e.T4248A81266293. doi:10.2305/IUCN.UK.2015-4.RLTS.T4248A81266293.en
- Mäkinen V.M., Mäyrä A., Munukka E. (2019) Improving the health of teeth in cats and dogs with live probiotic bacteria. *Journal of Cosmetics, Dermatological Sciences and Applications* 9: 275–283. doi:10.4236/jcda.2019.94024
- Marsh P.D. (2006) Dental plaque as a biofilm and a microbial community - implications for health and disease. *BMC Oral Health* 6(1): 14. doi:10.1186/1472-6831-6-S1-S14
- Meurman J.H., Stamatova I. (2007) Probiotics: Contributions to oral health. *Oral Diseases* 13(5): 443–451. doi:10.1111/j.1601-0825.2007.01386.x
- Nadkerny P.V., Ravishankar P.L., Pramod V., Agarwal L.A., Bhandari S. (2015) A comparative evaluation of the efficacy of probiotic and chlorhexidine mouthrinses on clinical inflammatory parameters of gingivitis: A randomized controlled clinical study. *Journal of Indian Society of Periodontology* 19(6): 633–639. doi:10.4103/0972-124X.168491
- Nanavati G., Prasanth T., Kosala M., Bhandari S.K., Banotra P. (2021) Effect of probiotics and prebiotics on oral health. *Dental Journal of Advance Studies* 9(1): 1–6.
- Pavlica Z., Petelin M., Juntos P., Eržen D., Crossley D.A., Skalerič U. (2008) Periodontal disease burden and pathological changes in organs of dogs. *Journal of veterinary dentistry*, 25(2): 97–105.
- Pessutti C., Santiago M.E.B., Oliveira L.T.F. (2001) Order Carnivora, Family Canidae (dogs, foxes, maned wolves). In: Fowler M.E., Cubas Z.S. (eds.). *Biology, Medicine, and Surgery of South American Wild Animals. 1st ed.* Ames, Iowa: Iowa State University Press, 279–290.
- Reis R.N., Peracchi A.L., Pedro W.A., Lima I.P. (2006) *Mammals of Brazil*. Londrina, Brazil: Federal Rural University of Rio de Janeiro, 244–245.
- Rossi Junior J.L. (2007) Evaluation of the Stomatognathic System and Sincraniums of Jaguar (*Panthera onca*) and Puma (*Puma concolor*) Captured or Collected in Nature. São Paulo, Brazil: DSc Thesis, Faculty of Veterinary Medicine and Animal Science, University of São Paulo.
- Ruiz-Miranda C.R., Grativol A.D., Sabatini V., Oliveira C.R., Faria G.V., Morais M.M. (2003) Etologia e conservação. In: Del-Claro K., Prezoto F. (eds.). *As Distintas Faces do Comportamento Animal*. Jundiá, Brazil: SBET – Sociedade Brasileira de Etologia & Livraria Conceito, 199–210.
- Saha S., Tomaro-Duchesneau C., Tabrizian M., Prakash S. (2012) Probiotics as oral health biotherapeutics. *Expert Opinion on Biological Therapy* 12(9): 1207–1220. doi:10.1517/14712598.2012.693474
- Santos Júnior T.S. (2005) Mamíferos do Cerrado de Mato Grosso, com Ênfase no Uso do Espaço por *Cerdocyon thous* (Carnivora, Canidae) e *Mazama gouazoubira* (Artyodactyla, Cervidae). São Carlos, Brazil: Dissertation. Universidade Federal de São Carlos.
- Song D., Liu X.R. (2020) Role of probiotics containing *Lactobacillus reuteri* in adjunct to scaling and root planing for management of patients with chronic periodontitis: A meta-analysis. *European Review for Medical and Pharmacological Sciences* 24(8): 4495–4505.
- Stepaniuk K. (2019) Periodontology. In: Lobprise H.B., Dodd J.R. (eds.). *Wiggs's Veterinary Dentistry: Principles and Practice*. Hoboken, New Jersey: Wiley Blackwell, 81–108.
- Taveira U., Matos M.B. (2010) Manejo alimentar de primatas em cativeiro. *Revista Eletrônica Nutritime* 7(2): 1175–1179.
- Teughels W., Durukan A., Ozcelik O., Pauwels M., Quirynen M., Haytac M.C. (2013) Clinical and microbiological effects of *Lactobacillus reuteri* probiotics in the treatment of chronic periodontitis: A randomized placebo-controlled study. *Journal of Clinical Periodontology* 40(11): 1025–1035. doi:10.1111/jcpe.12155
- Vives-Soler A., Chimenos-Küstner E. (2020) Effect of probiotics complement non-surgical periodontal therapy in chronic periodontitis: A systematic review. *Medicina Oral, Patología Oral e Cirurgia Bucal* 25(2): e161–e167.
- Wiggs R.B., Lobprise H.B. (1997) *Veterinary Dentistry: Principles and Practice*. Philadelphia, Pennsylvania: Lippincott-Raven.