

Research article

## Retrospective pathology review of captive black rhinoceros *Diceros bicornis* in the EAZA Ex-situ Programme (1995–2022)

Katharina Radeke-Auer<sup>1</sup>, Marcus Clauss<sup>1</sup>, Julia Stagegaard<sup>2</sup>, Linda G.R. Bruins-Van Sonsbeek<sup>3</sup> and Javier López<sup>4</sup>

<sup>1</sup>Clinic for Zoo Animals, Exotic Pets and Wildlife, Vetsuisse Faculty, University of Zurich, Winterthurerstr. 260, 8057 Zurich, Switzerland

<sup>2</sup>Ree Park Safari, Stubbe Søvej 15, 8400 Ebeltoft, Denmark

<sup>3</sup>Rotterdam Zoo, PO Box 352, 3000 AM Rotterdam, The Netherlands,

<sup>4</sup>Chester Zoo, The North of England Zoological Society, Caughall Rd, Chester, CH2 1LH, UK

Correspondence: Marcus Clauss, email; mclauss@vetclinics.uzh.ch

**Keywords:** black rhinoceros, *Diceros bicornis*, disease, gastric ulcer, iron overload disorder, tooth wear

**Article history:**

Received: 13 Feb 2023

Accepted: 18 Apr 2023

Published online: 30 Apr 2023

**Abstract**

The husbandry of black rhinoceros *Diceros bicornis* is challenging due to a number of peculiar diseases affecting this species. Causes of mortality and morbidity were evaluated from 67 necropsy reports of black rhinos deceased in the EAZA Ex-situ Programme (EEP) in 1995–2022, and the prevalence of specific diseases were compared with previous surveys in the literature. Whereas some problems described as typical, such as haemolytic anaemia, aspergillosis or specific skin diseases presented at low prevalence, signs of iron overload disorder (IOD) were close to ubiquitous across animals, and skin disease, excessive tooth wear (often linked to impaction) and gastric ulceration were particularly prevalent. While this evaluation cannot add to understanding of the aetiology of these conditions, it emphasises the need to further investigate IOD and other diseases (which will require access to routine blood samples of both healthy and diseased animals facilitated by medical training). The findings also recommend further investigation of measures to reduce stress, possibly including that triggered by conspecifics as well as humans. Species-adequate nutrition still requires proactive approaches in providing dicot-based forages without resorting to monocot (grass) products.

### Introduction

According to the International Union for Conservation of Nature (IUCN), the black rhinoceros *Diceros bicornis* is Critically Endangered because of habitat loss and, most importantly, due to poaching (Emslie and Brooks 1999; IUCN 2021). A dramatic 96% decline in wild populations has resulted in numbers falling from 100,000 in 1960 to about 2,400 individuals in 1992. In spite of an increase to about 5,000 individuals in 2012 (Emslie 2013), the most recent population estimates are about 3,100 individuals of a population reported as ‘increasing’ (IUCN 2021), which reflects the volatile state of the species in the past decade. The black rhino therefore falls under the group

of megafauna for which ex-situ conservation efforts have been proposed as one crucial component for conservation of the species (Farhadinia et al. 2020).

The ex-situ management of black rhinos is challenging for several reasons. Black rhinos are browsers, which makes it logistically demanding to replicate their natural diet in an ex-situ setting (Clauss and Hatt 2006). They have a solitary lifestyle (Mukinya 1973) and a comparatively aggressive nature, which means that they cannot be kept in groups or in mixed species exhibits (Pilgrim and Biddle 2020). Recently, a low reproductive rate of the ex-situ population has raised concern (Edwards et al. 2015). Although quantitative assessments are difficult, black rhinos may be more susceptible to stress than white

*Ceratotherium simum* or greater one-horned *Rhinoceros unicornis* rhinos (Pilgrim and Biddle 2020). For example, stress indicators such as an increase in the concentration or variability of faecal cortisol metabolites were observed in black rhinos housed in enclosures with a high level of exposure to the public and animals kept constantly together as pairs, and a high variability of these metabolites was correlated to institution-specific mortality (Carlstead and Brown 2005).

Most particularly, black rhinos in human care are known for their susceptibility to several diseases rarely reported in other rhino species, such as superficial necrolytic dermatitis (SND), haemolytic anaemia (HA), idiopathic haemorrhagic vasculopathy syndrome and iron overload disorder (IOD) (Dennis et al. 2007; Miller and Buss 2015). To the authors' knowledge, the only trend described in these diseases is a decrease in the incidence of HA after a peak in the 1990s (Miller and Buss 2015). IOD might be a common denominator for several of the black rhino's health problems, either as a causative factor or a consequential finding (Paglia and Dennis 1999; Paglia and Radcliffe 2000; Paglia et al. 2001; Schook et al. 2015).

An exhaustive analysis of the EEP population has not been carried out, so it is not known if this population suffers from the same conditions as other studied populations, or if advances in husbandry are resulting in changes in the trends for these diseases. In this study, necropsy reports of the EEP black rhino population from 1995 to 2022 were evaluated. The aim was to assess the causes of death and commonly reported pathological findings and their trends over time, to compare these findings with previously published reports to assess changes in the relevance of individual diseases over time and, in the case of IOD, to assess the degree to which it occurred and was reported alongside other findings.

## Materials and methods

This study was based on 81 black rhinos (30 males, 49 females, 2 of unknown sex) of the EEP that died between January 1995 and February 2022. These animals lived in 17 institutions and 6 European countries. Necropsy reports were requested by the EEP Rhino TAG. Reports that were not submitted in English or German were translated using web-based translations of medical terms. From each report, the following data were recorded: age at death, sex, death type (spontaneous, euthanasia or unknown) and, if stated, body condition and body mass, as well as the reported cause of death and other pathological findings not considered the cause of death. Body mass information represented actual weight noted on the report; estimates were not used. In some cases, more than one cause of death was reported and all were counted. If a cause of death was not clearly indicated, one was identified based on the pathology described in the report. The following organ system categories were utilised to group causes of death and comorbidities: integumentary, neurological (central and peripheral nervous system), cardiovascular, respiratory, dental, gastrointestinal, hepatic, renal, musculoskeletal and whole body/multi-organ failure. For neonates, additional causes of death noted included abortion and stillbirth, dystocia and congenital disease.

Depending on age at death, animals were categorised in five age groups to generally correspond with life stages according to Edwards et al. (2015): infant (0–1 year, including abortions and still births), subadult (1–5 years), young adult (6–17 years), adult (18–32 years) and post-reproductive (33 years and older).

The data were summarised according to the primary cause of death, reported diseases or findings ('comorbidities'), including specific pathogens if these had been isolated, and age class. Due to the low sample size, the summary was not split by both age group and sex, but sex is mentioned in selected circumstances.

To estimate the prevalence of IOD under different scenarios of scrutiny, information on whether this condition had been specifically looked for was also included, based on whether IOD was reported as present, absent or not mentioned at all. There was no standard terminology for IOD in the submitted reports; terms like haemosiderosis, hemochromatosis and intracellular iron pigment were used without a detectable gradation (e.g. haemosiderosis and necrosis were at times mentioned for the same cells). Therefore, all specific mentions of iron deposits were noted as IOD.

Reported body mass was plotted against age, expecting the common pattern of an increase during adolescence and stabilisation during adulthood, to visually assess whether body mass corresponded to the reported body condition and whether reported tooth wear or IOD were related to body mass. Body masses of adult animals were compared according to body condition and tooth wear (where reported) by ANOVA and subsequent Tukey post hoc test, testing residuals for normality. The body masses of males and females were compared by t-test. Analyses were performed in R (R Core Team 2020). Due to the generally low sample size, further evaluations beyond descriptive statistics were not applied. Findings of the present study were compared to prevalence data from various literature sources.

## Results

A total of 67 reports (82% of all animals that died in the investigated period; including 23 males, 43 females and one infant of unknown sex) were received. These reports varied in detail, quality and scope, from a one paragraph summary of findings to a full, descriptive report of gross and histological examination as well as ancillary testing. Histological details were missing in 19 (28%) reports. Although all the information available from the reports was used, the results most likely represent underestimates since reports were often incomplete. For example, if a report only indicated trauma as the cause of death but did not give information on organ systems, this automatically leads to a possible underestimation of the prevalence of organ system problems in the study population.

### Main causes of death

The distribution of the reported main causes of death across the age categories is indicated in Table 1. Across the whole population, the most frequent cause of death was gastrointestinal disease at 22%, followed by renal disease at 10%. In general, deaths appeared spread across a large variety of primary causes rather than indicating a specific, frequent problem.

The main cause of death for infants (age group 0–1 years) was abortion/stillbirth (n=5), followed by congenital disease (n=4) and dystocia (n=3). One abortion was related to a *Coxiella* infection; a stillbirth was related to a necrotising placentitis of suspected viral origin. The four congenital defects included a Fallot's tetralogy, a spina bifida and cerebral herniation, a patent ductus arteriosus with ventricular septal defect and a 300 g aborted foetus with an encephalocele and gastroschisis. Other causes of death included trauma (one neonate killed by a male giraffe in a mixed species exhibit), one calf dying with a gastrointestinal impaction by lucerne fibres and one calf born overnight suffocating because the mother failed to remove the foetal membranes.

In subadults (age group 1–5 years, n=4), causes of death were myocarditis (n=1), superficial necrolytic dermatitis (SND, n=1), an oesophageal obstruction caused by unidentified material (n=1) and death during anaesthesia for horn removal (n=1).

In young adults (age group 6–17 years, n=14), gastrointestinal disease was the single most common finding (n=4), represented by one necrotising, one fibrinous and one unspecified

**Table 1.** Distribution of primary causes of death\* by affected organ systems across age categories in dead black rhinoceroses *Diceros bicornis* in the EAZA Ex-situ Programme (1995-2022). \*in some cases, more than one primary cause of death was listed. °these three cases of liver disease were all attributed to severe iron overload disease.

Age class	Infant 0-1 yr	Subadult 1-5 yr	Young adult 6-17 yr	Adult 18-32 yr	Post-reprod. 33+ years	Total
Number of cases (male.female.unknown)	15 (5.9.1)	4 (1.3.0)	14 (6.8.0)	21 (8.13.0)	13 (3/10/0)	67 (23/43/1)
Spontaneous/Euthanasia	15/0	3/1	10/4	15/6	8/5	51/16
Skin disease	-	1 (25%)	2 (14%)	1 (5%)	-	4 (6%)
Neurological disease	-	-	1 (7%)	-	-	1 (1%)
Cardiovascular disease	-	1 (25%)	1 (7%)	1 (5%)	1 (8%)	4 (6%)
Respiratory disease	-	-	1 (7%)	2 (10%)	2 (15%)	5 (7%)
Gastrointestinal disease	1 (7%)	1 (25%)	4 (29%)	8 (38%)	1 (8%)	15 (22%)
Liver disease	-	-	-	3 (14%)°	1 (8%)	4 (6%)
Renal disease	-	-	2 (14%)	2 (10%)	3 (23%)	7 (10%)
Musculoskeletal disease	-	-	-	-	2 (15%)	2 (3%)
Multi-organ failure	-	-	-	1 (5%)	3 (23%)	4 (6%)
Miscellaneous						
Abortion/Stillbirth	5 (33%)	-	-	-	-	5 (7%)
Dystocia	3 (20%)	-	-	-	1 (8%)	4 (6%)
Congenital disease	4 (27%)	-	-	-	-	4 (6%)
Haemolytic anaemia	-	-	2 (14%)	1 (5%)	-	3 (4%)
Trauma	1 (7%)	-	-	-	1 (8%)	2 (3%)
Other	1 (7%)	1 (25%)	3 (21%)	4 (19%)	-	9 (13%)

enteritis and an impalement of a wooden foreign body in the oesophagus. Haemolytic anaemia, SND and nephropathies were represented with two cases each. Individual cases of neurological, cardiovascular and respiratory disease were also observed.

In adults (age group 18–33 years, n=21), the most prevalent cause of death was gastrointestinal disease (n=8). These included an oesophageal obstruction with a bolus of lucerne and another case of an ulcerated oesophagus, a gastric rupture due to severe ulceration, four cases of large intestine obstruction (due to sand or gravel in three cases and unspecified in the fourth) and a generalised enteritis. There were three cases of hepatopathies, all reported as liver insufficiency due to IOD, and one case each of haemolytic anaemia and SND.

In post-reproductive animals (age group 33 years and older, n=13), nephropathies and multi-organ failure were represented with three cases each, and there were two cases of animals with severe arthritis or pododermatitis/osteomyelitis and two cases ascribed to respiratory disease.

#### **Body mass, body condition and comorbidities**

The distribution of body mass, body condition and reported diseases irrespective of the cause of death (comorbidities) across the age groups is indicated in Table 2. The majority of comorbidities presented at high prevalence, including IOD (see below), gastrointestinal disease (in 46% of all animals, 12 males 19 females), skin disease (40%, 7 males 20 females), respiratory disease (40%, 9 males 18 females), liver disease (37%, 6 males 19 females), renal disease (34%, 4 males 19 females), cardiovascular

disease (25%, 6 males 11 females) and excessive tooth wear (25%, 4 males 13 females). It should be noted that there were nearly twice as many females as males in the whole sample.

Body mass data was given for 40 animals. For adult individuals (n=30), there was no significant difference in body mass between males (966±151 kg) and females (924±178 kg, P=0.511). There was no evident trend of body mass with age; both highest and lowest body masses of adults were recorded between 27 and 35 years (Figure 1). Body condition was judged in 46 animals. The proportion of individuals in poor body condition increased with age. In animals for which both body mass and body condition information was available, it appeared that the body condition evaluation reflected the body mass of the animals (Figure 1A); in particular, the body mass of animals reported in poor condition (816±130 kg) was significantly lower than that of animals reported in moderate condition (994±99 kg, P=0.009) and that of animals reported in good condition (1119±182 kg, P<0.001).

Gingivitis or tartar, as well as excessive tooth wear, showed an accumulation with age, but with a peak in the 18–32 age group and a decline in prevalence in the 33+ group (Table 2). Excessive tooth wear was very frequently reported in adult and post-reproductive animals but there was no clear association with age-specific body mass (Figure 1B); the ANOVA indicated no significant difference (P=0.520) between animals for which excessive tooth wear was not mentioned (968±202 kg), was absent (858±175 kg) or was present (885±138 kg). Other conditions increasing with age include liver diseases and nephropathies, whereas dermatopathies and gastrointestinal problems including

**Table 2.** Distribution of body mass, body condition, reported health issues\* and isolated pathogens (irrespective of whether they represented the cause of death or not) across age categories in dead black rhinoceroses *Diceros bicornis* in the EAZA Ex-situ Programme (1995-2022). \* several diseases per animal possible, °excluding aborted foetuses, †mean of animals from 6 years onwards, #count of reports that mention whether the animal has IOD or not.

Age class	Infant 0-1 yr	Subadult 1-5 yr	Young adult 6-17 yr	Adult 18-32 yr	Post-reprod. 33+ years	Total
n	15	4	14	21	13	67
(male.female.unknown)	(5.9.1)	(1.3.0)	(6.8.0)	(8.13.0)	(3/10/0)	(23/43/1)
Body mass (kg; mean, range)	32 (23-44)°	713 (650-800)	954 (819-1065)	1008 (560-1500)	940 (650-1400)	974† (819-1500)
Body condition (good/ average/ poor; not given)	(1/1/0; 13)	(3/0/1; 0)	(1/6/4; 3)	(5/5/7; 4)	(3/1/7; 2)	(13/13/19; 22)
Skin disease	1 (7%)	1 (25%)	8 (57%)	11 (52%)	6 (46%)	27 (40%)
Neurological disease	-	-	2 (14%)	2 (10%)	2 (15%)	6 (9%)
Cardiovascular disease	-	3 (75%)	4 (29%)	7 (33%)	3 (23%)	17 (25%)
Respiratory disease	2 (13%)	1 (25%)	7 (50%)	10 (48%)	7 (54%)	27 (40%)
Dental						
Gingivitis/Tartar/Stomatitis	-	1 (25%)	2 (14%)	9 (76%)	1 (8%)	13 (19%)
Excessive tooth wear	-	-	1 (7%)	10 (48%)	6 (46%)	17 (25%)
Gastrointestinal disease	2 (13%)	1 (25%)	9 (64%)	12 (57%)	7 (54%)	31 (46%)
Stomach ulceration	-	1 (25%)	6 (43%)	9 (43%)	4 (31%)	20 (30%)
Liver disease	1 (7%)	2 (50%)	5 (36%)	9 (43%)	8 (62%)	25 (37%)
Renal disease	-	1 (25%)	5 (36%)	9 (43%)	8 (62%)	23 (34%)
Pododermatitis/Laminitis	-	1 (25%)	1 (7%)	-	6 (46%)	8 (12%)
Miscellaneous	1 (7%)	1 (25%)	7 (50%)	15 (71%)	10 (77%)	34 (51%)
Hypophosphatemia	-	-	1 (7%)	-	-	1 (1%)
Haemolytic anaemia	-	-	2 (14%)	1 (5%)	-	3 (4%)
Iron overload disorder						
(of all animals)	1 (7%)	3 (75%)	10 (71%)	18 (86%)	8 (62%)	40 (60%)
#animals tested	9	4	10	18	8	49
#(of all tested animals)	3 (33%)	3 (75%)	10 (100%)	18 (100%)	8 (100%)	40 (82%)
Herpesvirus	-	-	1 (7%)	-	-	1 (1%)
<i>E. coli</i>	2 (13%)	1 (25%)	2 (14%)	3 (14%)	1 (8%)	9 (13%)
<i>Clostridium</i> spp.	-	1 (25%)	1 (7%)	3 (14%)	-	5 (7%)
<i>Salmonella</i>	-	-	1 (7%)	-	1 (8%)	2 (3%)
<i>Aspergillus</i>	-	-	-	2 (10%)	1 (8%)	3 (4%)

stomach ulcerations had a relatively constant prevalence across age groups. Among the dermatopathies, eight cases reported ulcerative lesions without making the diagnosis of SND (but also without excluding it). Stomach ulcerations were frequently reported (n=20). Gravel or sand in the intestine was reported in five individuals. Pododermatitis was diagnosed in subadult as well as very old animals. Heart problems appeared to decrease with age (Table 2).

In animals older than 5 years, signs of IOD were evident in all individuals in which it had been specifically investigated. One subadult animal and two neonates were reported as negative for signs of IOD (Table 2). Due to the high prevalence of IOD, there was no evident relationship with age-specific body mass (Figure 1C) and there was no other specific condition that occurred particularly frequently in association with IOD signs (Tables 3–5).

Miscellaneous problems observed include, amongst others, four cases of adrenal inflammation, two cases of ovarian cysts, arthrosis, skeletal muscle damage and different parasites.

When compared to previous similar compilations of post mortem results, the absence of mycobacteriosis and leptospirosis, the low prevalence of aspergillosis and the high prevalence of *Clostridium* spp. and *E. coli* were notable among the infectious diseases (Table 3). The prevalence of skin disease, pododermatitis, renal disease and dental problems were higher in the present study than previously reported (Table 4). By contrast, among the known black rhino-specific diseases, idiopathic vasculopathy syndrome, haemolytic anaemia, leukoencephalomalacia, eosinophilic granuloma syndrome and hypophosphatemia showed a lower prevalence than previously reported, and only signs of IOD were higher than previously reported (Table 5).

**Table 3.** Infectious pathogens reported to be relevant for black rhinoceroses *Diceros bicornis* with their prevalence in the literature for specific time periods, and the recorded comorbidity with iron overload disorder (IOD; in % of all animals tested for IOD). <sup>1</sup>[Jarofke et al. 1991], <sup>2</sup>[Munson et al. 1998], <sup>3</sup>[Mann et al. 1981; Barbiers 1994; Valandikar and Raju 1996; Espie et al. 2009; Bryant et al. 2012; Miller and Buss 2015; Miller et al. 2017], <sup>4</sup>[Taugner et al. 1995; Kenny 1999; Miller et al. 2008; Miller and Buss 2015], <sup>5</sup>[Douglass and Plue 1980; Miller and Bolin 1988; Jessup et al. 1992; Neiffer et al. 2001; Miller and Buss 2015], <sup>6</sup>[Taugner et al. 1995; Ndeereh et al. 2012], <sup>7</sup>[Taugner et al. 1995; Miller and Buss 2003], <sup>8</sup>[Miller and Buss 2003], <sup>9</sup>[Taugner et al. 1995; Weber and Miller 1996].

Pathogen	Sample	n	Prevalence	IOD comorbidity (% of all tested)
<i>Mycobacterium</i>	cases/series <sup>3</sup>			
	studbook, 1970-1990 <sup>1</sup>	151	5%	
	SSP dermatitis cases, 1989-1994 <sup>2</sup>	34	6%	
<i>Salmonella</i>	cases/series <sup>4</sup>			
	studbook, 1970-1990 <sup>1</sup>	151	1%	
	SSP dermatitis cases, 1989-1994 <sup>2</sup>	34	3%	
<i>Leptospira</i>	cases/series <sup>5</sup>			
	studbook, 1970-1990 <sup>1</sup>	151	1%	
	SSP dermatitis cases, 1989-1994 <sup>2</sup>	34	0%	
<i>Clostridium</i>	cases/series <sup>5</sup>			
	studbook, 1970-1990 <sup>1</sup>	151	1%	
	SSP dermatitis cases, 1989-1994 <sup>2</sup>	34	0%	
<i>E. coli</i>	cases/series <sup>7</sup>			
	studbook, 1970-1990 <sup>1</sup>	151	1%	
	SSP dermatitis cases, 1989-1994 <sup>2</sup>	34	0%	
<i>Aspergillus</i>	cases/series <sup>8</sup>			
	studbook, 1970-1990 <sup>1</sup>	151	5%	
	SSP survey, 1980-1994 <sup>9</sup>	57	14%	
	SSP dermatitis cases, 1989-1994 <sup>2</sup>	34	18%	
	this study, 1995-2022	67	4%	100%

With no mention in 55% and 63% of reports, respectively, reproductive tract and the central nervous system were among the most underreported areas.

## Discussion

Evaluation of more recent (1995–2022) necropsy reports of black rhinoceros in European facilities indicates a variety of health issues to be relevant for the species. It does not show a high prevalence of many of the specific disorders reported for the species but corroborates the observation that in particular, cases of haemolytic anaemia seem to be rarer than in previous decades (Miller and Buss 2015). By contrast, it emphasises once more the generalised susceptibility of black rhinos to accumulate iron in various organs.

## Limitations of the study

Before discussing the findings, severe limitations that apply to endeavours to summarise necropsy reports and notes on the cause of death from a variety of institutions for any species should be mentioned. The lack of consistency in the quality of post-mortem examination and reporting significantly impairs the extraction of precise information. Judging the degree of severity of pathologic conditions, e.g. the severity of IOD, from reports from different institutions is inherently difficult. Also, it is impossible to evaluate whether a blank line, a lack of mention or even a generic statement such as “all other organs normal” indicates no pathological findings or if the corresponding organs were not examined or only examined superficially. Such uncertainties affect conclusions regarding any organ; some examples are the feet, the oral cavity, the stomach mucosa, reproductive organs and the

**Table 4.** Non-infectious diseases reported to be relevant for black rhinoceroses *Diceros bicornis* with their prevalence in the literature for specific time periods, and the recorded comorbidity with iron overload disorder (IOD; in % of all animals tested for IOD). <sup>1</sup>[Jarofke et al. 1991], <sup>2</sup>[Dennis 2004], <sup>3</sup>[Munson et al. 1998], <sup>4</sup>[Miller and Buss 2003], <sup>5</sup>[Murnane et al. 1994; Miller and Buss 2003], <sup>6</sup>[Munson et al. 1998; Radcliffe et al. 2000; Miller and Buss 2003; Portas et al. 2010; Wack et al. 2010], <sup>7</sup>[Miller and Buss 2003; Beagley et al. 2010].

Disease	Sample	n	Prevalence	IOD comorbidity (% of all tested)
Dermatitis / Dermopathy	studbook, 1970-1990 <sup>1</sup>	151	3%	
	SSP survey, 1930-2001 <sup>2</sup>	296	19%	
	SSP survey, 1989-1994 <sup>3</sup>	80	~50%	
	this study, 1995-2022	67	39%	100%
Pododermatitis / Laminitis	cases/series <sup>4</sup>			
	studbook, 1970-1990 <sup>1</sup>	151	0%	
	this study, 1995-2022	67	12%	100%
Glomerulopathy / Nephritis	cases/series <sup>5</sup>			
	studbook, 1970-1990 <sup>1</sup>	151	3%	
	this study, 1995-2022	67	34%	100%
Neoplasia	cases/series <sup>6</sup>			
	studbook, 1970-1990 <sup>1</sup>	151	3%	
	this study, 1995-2022	67	6%	100%
Dental issues (wear, calculus, loss)	cases/series <sup>7</sup>			
	studbook, 1970-1990 <sup>1</sup>	151	0%	
	SSP survey, 1930-2001 <sup>2</sup>	296	7%	
	this study, 1995-2022	67	30%	100%

central nervous system. These organs or locations are relatively likely not to be investigated, in particular if an evident cause of death is diagnosed early on during the pregnancy. Thus, ovarian cysts were diagnosed in two adult females, uterine tumours in two others and an endometritis in another single animal. Given the comparatively high proportion of non-reproductive females in the black rhino EEP, estimated at over 40% of adult females by Edwards et al. (2015), this low prevalence of findings on the reproductive tract is suspicious. Similarly, the complete absence of reports of pododermatitis or arthritis in the 18–32 year age group does not appear likely, given the high prevalence in the 33+ age group and the likelihood that many animals were kept on comparatively hard substrates for a large part of their life (cf. the susceptibility of another rhino species kept on hard substrates; von Houwald 2016). The absence of histological findings in 19 of the 67 necropsy reports is another testimony of the difficulty to draw definitive conclusions from this study. While the overall impression is that there are no sex-specific diseases (apart from those related to the genital tract), the low sample size precludes any certainty; it appears prudent to consider both sexes equally susceptible to most diseases. Finally, a lack of reporting (as confirmation or specific absence) of diseases peculiar to black rhinos may stem from unfamiliarity of the person performing

the necropsy and histopathology with the black rhino literature. Therefore, the findings of the present evaluation should not be considered conclusive but indicative of potentially important issues in zoo-managed black rhinos.

#### **Skin-related problems**

From six years of age onwards, various degrees of skin lesions affected more than half of the animals, ranging from a few cases of noted shallow abrasions to multiple severe, ulcerative and purulent lesions. Compared to previous general surveys on black rhino diseases (Table 4) but similar to the most specific one directed at skin disease (Munson et al. 1998), the high prevalence of skin problems is a major finding of the present study. The relevance of black rhino skin pathology has been previously recognised (Munson and Miller 1999), with animals of all ages affected and no increase in prevalence with age (Dorsey et al. 2010). From the necropsy reports, it was often not possible to ascertain whether the observed lesions corresponded to specific skin problems described for the species. No cases of ‘idiopathic haemorrhagic vasculopathy syndrome’ (Murray et al. 1999) or ‘cutaneous eosinophilic granuloma’ (Pessier et al. 2004) were reported; in only five cases ‘superficial necrolytic dermatitis’ (Miller and Buss 2003; Munson et al. 1998) was identified. The



**Table 5.** Specific diseases reported to be relevant for black rhinoceroses *Diceros bicornis* with their prevalence in the literature for specific time periods, and the recorded comorbidity with iron overload disorder (IOD; in % of all animals tested for IOD). \*cases in which a test for iron deposits was reported <sup>1</sup>[Munson et al. 1998; Miller and Buss 2003], <sup>2</sup>[Murray et al. 2000], <sup>3</sup>[Dennis 2004], <sup>4</sup>[Chaplin et al. 1986; Paglia 1993; Paglia 1994; Taugner et al. 1995], <sup>5</sup>[Miller and Boever 1982], <sup>6</sup>[Munson et al. 1998], <sup>7</sup>[Kenny et al. 1996; Miller 1996; Paglia et al. 2001], <sup>8</sup>[Miller and Buss 2003; Pessier et al. 2004], <sup>9</sup>[Miller and Boever 1982; Paglia 1993; Murray et al. 2000], <sup>10</sup>[Dennis 2004], <sup>11</sup>[Kock et al. 1992; Strauss and Wisser 1995; Taugner et al. 1995; Paglia and Dennis 1999; Miller and Buss 2003; Clauss and Paglia 2012; Olias et al. 2012; Paglia and Tsu 2012].

Disease	Sample	n	Prevalence	IOD comorbidity (% of all tested)
Superficial necrolytic dermatitis	cases/series <sup>1</sup> this study, 1995-2022	67	7%	100%
Idiopathic hemorrhagic vasculopathy syndrome	cases/series <sup>2</sup> SSP survey, 1930-2001 <sup>3</sup> this study, 1995-2022	296 67	7% 0%	-
Hemolytic anaemia	cases/series <sup>4</sup> SSP survey, 1972-1982 <sup>5</sup> studbook, 1970-1990 <sup>1</sup> SSP dermatitis cases, 1989-1994 <sup>6</sup> this study, 1995-2022	29 151 34 67	48% 8% 9% 4%	~100% - 100%
Leukoencephalomalacia	cases/series <sup>7</sup> studbook, 1970-1990 <sup>1</sup> SSP dermatitis cases, 1989-1994 <sup>6</sup> this study, 1995-2022	151 34 67	1% 1% 0%	-
Eosinophilic granuloma syndrome	cases/series <sup>8</sup> this study, 1995-2022	67	0%	-
Hypophosphataemia	cases/series <sup>9</sup> SSP survey, 1930-2001 <sup>10</sup> this study, 1995-2022	296 67	11% 1%	100%
Iron overload disorder	cases/series <sup>11</sup> SSP survey, 1930-2001 <sup>10</sup> this study, 1995-2022	296 67 44*	16% 60% 91%	

majority of skin problems reported may have related to other aetiologies (with no general pattern emerging from the necropsy reports) or pathologists performing the necropsies may not have been familiar with rhino-specific skin pathology. The fact that in eight cases ulcerative lesions were reported yet SND was not mentioned could support the latter interpretation. Skin problems occurred in conjunction with other health problems. The predisposing factors to developing skin pathology in black rhinos are not well understood, but stress has been suggested as a potential cause. Munson et al. (1998) related skin problems to stress episodes, listing transport, cold spells, intraspecific conflict, oestrus, advanced pregnancy and other diseases, emphasising the species' stress susceptibility. Dorsey et al. (2010) found decreased glucocorticoid concentrations in the faeces of black rhinos affected by skin lesions; low glucocorticoid levels have been interpreted as a sign of distress in rhino species (Linklater et al. 2010).

#### Excessive tooth wear

Excessive tooth wear at post-mortem examination was reported

for a larger number of animals (30%) than in previous surveys (0–7%; Table 4). This may represent either increasing prevalence or an increased attention paid to the oral cavity in rhino necropsies. Excessive tooth wear peaked in the 18–32 age group. This could indicate that dental issues represent an important senescence factor that might limit the life expectancy of captive black rhinos. In 7 of the 10 cases with excessive wear in the 18–32 age group, and in 2 of the 6 cases in the 33+ age group, the necropsy reports included notes about impaction/obstipation at various locations in the gastrointestinal tract (7 cases) and insufficiently chewed stomach contents (2 cases), underlining the clinical relevance of tooth health. Increased dental wear in zoo-managed black rhinos, as compared to free-ranging conspecifics, has been suggested based on comparisons of museum specimens (Taylor et al. 2014).

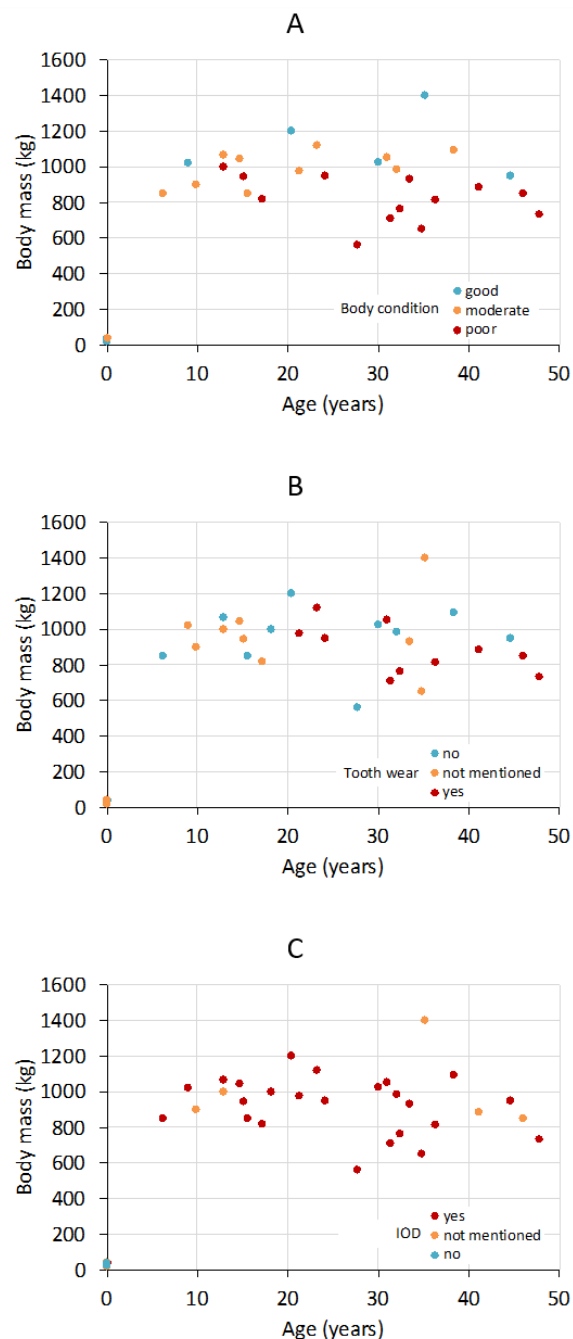
There has been a long-standing debate on the major causes of dental wear in mammalian herbivores—in particular, whether this is primarily due to external abrasives, i.e. dust, grit and sand, or abrasives that are internal to food items, in particular the phytoliths embedded in monocotyledonous plant material

(grasses) (e.g. Ackermans et al. 2020; Merceron et al. 2016; Sanson et al. 2017; Schulz-Kornas et al. 2020; Winkler et al. 2019). The consensus is that both kinds of abrasives should be considered triggers for tooth wear. In grazing animals that feed close to the ground, such as the white rhinoceros, both kinds of abrasives can be expected to be more prominent compared to the black rhino. As a browser, the black rhino feeds higher above the ground, away from abrasive sand and on dicotyledonous plants that scarcely harbour phytoliths. This should have influenced the evolutionary adaptation for durable teeth in rhinos, as suggested by white rhinos having higher-crowned teeth than black rhinos (Janis 1988), and it will have an effect on the susceptibility to wear due to contamination with sand or soil, and due to food that is grass-based and contains phytoliths. When compared to free-ranging conspecifics, rhinos managed in zoos have comparatively increased tooth wear in black, and comparatively decreased tooth wear in white, rhinos. This may indicate a feeding regime that prevents the dust and grit load that white rhinos face in the wild but includes more dust and grit and more phytolith-rich grass components in the black rhino diet (Taylor et al. 2014). Food offered to rhinos in zoos is often based on grass hay or pelleted feeds containing grass hay or the bran or husks of grains, which are rich in phytoliths and may result in increased tooth wear. Avoiding feeds with a high level of abrasiveness is therefore a reasonable strategy in black rhinos and would affect the choice of forage (for instance phytolith-rich grass versus phytolith-free alfalfa hay; phytolith-free browse) as well as that of compound feeds of a specific composition (Clauss et al. 2007a). Additionally, feeding black rhinos in such a way that accidental ingestion of soil is minimised should further protect their teeth (Jurado et al. 2008) and should be advised, especially since pathological levels of sand or gravel in the intestines were reported in five animals.

Examining teeth in live rhinos is challenging and would in most cases at least require a standing sedation, if not a full immobilisation. Therefore, close observation of chewing behaviour and regular checks of faecal particle size should be part of the rhino monitoring routine, as early warning signs. In the evaluation of dental status of black rhinos, a word of caution seems appropriate. The chewing patterns and dental wear patterns differ between grazing rhinos and those animals veterinarians are most familiar with in terms of teeth—horses—on the one hand (Figure 2A), and browsing rhinos (both from extant species and the fossil record) on the other. Browsing rhinos have a bi-phasic chewing movement (Fortelius 1982; Fortelius 1985; von Koenigswald et al. 2013) that comprises a vertical movement of the lower teeth against the upper ones, leading to a ‘cutting’ action (von Koenigswald 2018). This is then followed by a grinding action as the lower tooth slides across the remaining, lingual part of the upper (Figure 2B). The consequence of this morphology and chewing movement, together with an inward rotation of teeth over time (Fortelius 1982), is that upper teeth in browsing rhinos appear to wear down more on the lingual than the buccal side, forming a prominent ridge along the buccal edge of the upper cheek teeth (Figure 2C). This is in contrast to white and greater one-horned rhino cheek teeth, in which a configuration similar to that of horses is achieved. When evaluating the dental status of black rhinos, it is important not to confuse the natural buccal ridge with ‘tips’ that need to be filed down.

#### Gastrointestinal pathology and feeding

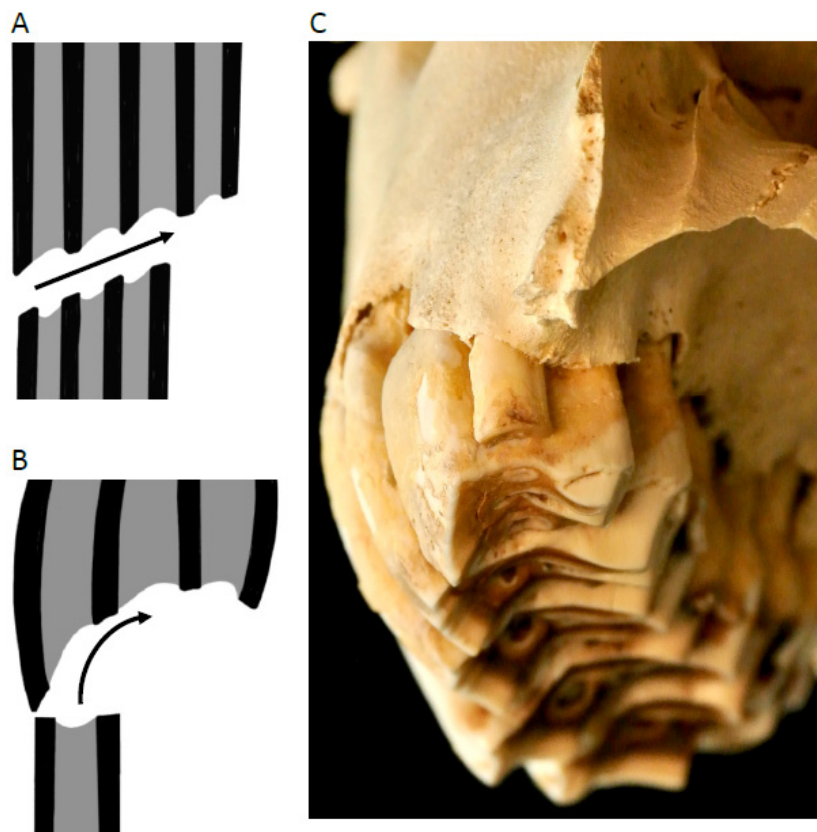
Gastrointestinal tract (GIT) pathology affected more than half of all animals from six years of age onwards and was related to a variety of causes including obstructions and enteritis. Gastric ulcers represented a surprisingly high proportion of the GIT findings of the present survey—in 20 of the 31 cases of GIT problems, gastric ulcerations were involved. It was not possible to judge whether



**Figure 1.** Relationship of body mass with age in necropsy reports of zoo-kept black rhinoceros *Diceros bicornis* depending on (A) body condition, (B) presence of excessive tooth wear, (C) presence of signs of iron overload disorder (IOD).

these represented chronic events or ulcerations in the course of terminal disease, or the degree of the severity. In domestic horses, administration of non-steroidal anti-inflammatory drugs (NSAIDs) has been associated with gastric ulcerations (Flood and Stewart 2022); these ulcerations could therefore be related to medication the rhinos received prior to death. In domestic pigs, a low proportion of forage and a diet consisting of finely ground components is considered a major cause of gastric ulceration (Bertsch et al. 2022; Helbing et al. 2022). In domestic horses, intermittent feed intake; diets high in starch, sugars or concentrates





**Figure 2.** Schematic (A,B; symbols represent the upper and lower cheek dentition; the buccal side is the left and the lingual side to the right) and actual (C) right upper dental configuration of black rhinoceros *Diceros bicornis*; rostral view. Rather than a purely transverse chewing movement on the latero-medial plane as in horses or grazing rhinos (A), browsing rhinos including the black rhino have a bi-phasic chewing stroke with an orthal (vertical) component that is then followed by a transverse (latero-medial) component (B), leading to the typical buccal ridge in black rhino maxillary cheek teeth (C). Drawings by Emilia Clauss, photograph by Annika Avedik.

and low in roughage; stress; and a stress-sensitive personality are all considered contributory factors of gastric ulceration (e.g. Andrews et al. 2017; Galinelli et al. 2021; Malmkvist et al. 2012). In horses, lucerne hay instead of grass hay has been suggested to protect against ulcers, although the corresponding mechanism remains elusive (Bäuerlein et al. 2020). Both the absence of phytoliths and a putatively positive effect against stomach ulcers are reasonable arguments for using lucerne hay in black rhinos, whereas it has been suggested—without clinical evidence—that lucerne hay as the main forage is not suitable for black rhinos, predisposing them to diarrhoea, colic and mineral imbalances (Dierenfeld 1999).

As browsers, black rhinos are assumed to be more difficult to feed adequately than grazing herbivores (Clauss and Dierenfeld 2008). Generally, the diet of browsers often comprises less forage because browse is more difficult to provide than grass, and hence often a higher proportion of ‘concentrate’ is fed. Although comparative data on diets fed is lacking, higher faecal volatile fatty acid levels and, particularly, high levels of propionate in the faeces of zoo-kept black rhinos compared to other zoo-kept rhinos have been documented (Cersosimo et al. 2022; Roth et al. 2019). This is typically considered an indication of a higher proportion of easily

digestible carbohydrates in the diet (Clauss et al. 2005). A potential consequence could be a generally higher body condition in black rhinos compared to other zoo-managed rhino species. This would match the observation that zoo-managed black rhinos had lower insulin sensitivity than free-ranging specimens and the hypothesis that obesity could be an aetiological factor for iron overload and hypophosphataemia (Schook et al. 2015). Previously reported observations (Clauss and Hatt 2006) as well as the age-related body mass/body condition scores of the present study (Figure 1A) do not support the concept that the black rhino EEP population is obese but can also not exclude it, representing only deceased animals. In the absence of a body condition and body mass survey of the species, this remains speculative.

#### **Respiratory and urinary tract**

Lung lesions were common at all age classes and most likely include signs related to agony; the six cases in which only oedema and/or emphysema were reported could be interpreted in this way. Aspergillosis, previously reported as an important disease of black rhinos (Table 3), was only diagnosed in three cases. While this might reflect a lack of diagnostic effort, it could also testify increasing hygienic standards in rhino husbandry. However, in

11 of the 27 reported cases of respiratory disease, purulent processes or abscesses were observed, indicating that infections must represent a significant risk for rhinos.

Nephropathies increased steadily across the age groups and were distinctively more frequent than in a previous survey (Table 4). It was beyond the scope of this study to carry out an exhaustive assessment of renal pathology in rhinos, but it is clear that renal pathology is highly prevalent in the older rhino population. This should be borne in mind when planning health assessments and choosing therapies and anaesthetics for animals in these older age groups. No generalised pattern could be gleaned from the necropsy reports, but kidney diseases should receive particular attention in future black rhino health surveys.

### **Haemolytic anaemia**

Haemolytic anaemia was reported in three rhinos (aged 8, 9 and 32 years; 4% of the animals examined), which is lower than observed in previous studies (Table 5). HA has been diagnosed by confirmation of very low haematocrits, often accompanied by haemoglobinuria and jaundice (Miller and Boever 1982). In the three cases reported in this survey, HA was diagnosed based on the presence of haemoglobinuria in one case, on the presence of jaundice in the second and on a pre-mortem blood sample in the third. A lack of haematological assessment may result in under- or over-diagnosing this condition. To what degree this may occur is difficult to judge, but collecting blood samples during euthanasia and assessment of haematocrit, haemoglobin, bilirubin and possibly reticulocyte count and mean corpuscular volume measures are encouraged in order to provide a confident diagnosis of HA. HA has been linked to leptospirosis or specific intoxications (Miller and Buss 2015) but also to particularities in the erythrocytes of black rhinos, which have been later identified as common to all rhinoceros species (and hence cannot explain the susceptibility of the browsing species to HA or IOD) (reviewed in Paglia and Tsu 2012).

While the cause of the higher prevalence of HA in previous studies may remain unknown, data suggests that cases of HA are rarer than in previous decades, supporting a similar statement by Miller and Buss (2015). Since HA is a clinical condition that is best diagnosed *in vivo* and may be intermittent, health monitoring by regular blood sampling is recommended (Pilgrim and Biddle 2020) to obtain a clearer picture of its prevalence in the zoo black rhino population.

### **Iron overload disorder**

Excessive iron storage in various organs at necropsy and high iron serum analytes (in particular ferritin or transferrin saturation) have been reported in browsing rhinos for a very long time (reviewed in Clauss and Paglia 2012; Paglia and Tsu 2012). The current results contribute to that body of observations and show that this continues to be prevalent.

Tissue iron accumulation can be secondary to other diseases such as bacterial infections or severe cachexia (Lowenstine and Munson 1999). Signs of IOD cannot be interpreted as indicative of past episodes of HA in the absence of a history of haemoglobinuria and/or jaundice.

To what degree iron accumulation represents a health risk to the individual animal cannot be gleaned from necropsy reports, due to its omnipresence and the fact that standardised grading is not common practice in rhino necropsies. Ideally, histological slides of black rhinos should be examined by a single pathologist using a standardised grading system to assess the severity of the deposition and to differentiate pathological (haemochromatosis) from non- or pre-pathological (haemosiderosis) levels of iron accumulations in the organ. This will provide a better understanding of the development and progression of the condition and potential

contribution to other diseases. In this study, liver failure due to IOD was reported as the main cause of death in three animals. Whether the reporting of IOD as cause of death was justified or not cannot be decided; however, this reporting practice clearly emphasises the perceived severity of IOD.

IOD in general, and especially in black rhinos, is often a frustrating factor of zoo animal management due to its poorly understood aetiology, uncertainty of the extent to which it actually contributes to morbidity and mortality, and difficulties in prevention, *in vivo* diagnostics and treatment. To the authors' knowledge, little progress as to the aetiology and pathophysiology has been made in spite of extensive efforts (Pouillevet et al. 2020; Roth et al. 2019, 2022; Wojtusik et al. 2021). Currently, dietary measures aimed at reducing iron absorption or intake (Clauss et al. 2012) and phlebotomies to remove iron-rich blood from the system (Sullivan et al. 2020) are the main preventative options, as well as the evident deposition of iron into a foetus in breeding female animals. Diagnosing IOD remains challenging, and recent findings that serum ferritin is a poor predictor of the severity of iron accumulation (Wojtusik and Roth 2018) leaves transferrin saturation as the major easily attainable serum measurement to investigate further (Sullivan et al. 2020). As therapeutic measures, the mentioned phlebotomies and potential use of chelators have been described (Muneuchi et al. 2018; Sullivan et al. 2020) but to the authors' knowledge have not been widely applied in the EEP population.

Different aetiologies have been suggested for IOD, such as a general lack of an evolutionary acquired defence against iron uptake in conjunction with diets in zoos that contain more iron and less iron-chelating substances than natural diets (Clauss et al. 2007b; Paglia and Tsu 2012; Sullivan et al. 2020), or adiposity-induced inflammatory processes and reduced insulin sensitivity (Schook et al. 2015). Another aetiological factor might be generalised stress. Black rhinos have been described as generally more easily stressed than greater one-horned or white rhinos (Clauss and Hatt 2006; Pilgrim and Biddle 2020) and are often stressed by proximity to humans as well as conspecifics (Carlstead and Brown 2005). In both black and white rhinos, the stress caused by immobilisation for translocation of free-ranging animals resulted in a decrease of serum iron levels (Pohlin et al. 2020), indicating that iron is shunted out of the serum. This might resemble experiments in rats, in which disturbances of iron metabolism by psychological stress have been reported (Jiang et al. 2021) including a reduction in serum iron after acute stress (Spiers et al. 2022) and an increase in hepatic iron deposition due to short-term or chronic stress (Guo et al. 2020; He et al. 2011; Zhao et al. 2014). Psychological stress can also lead to increased inflammation markers (e.g. Spiers et al. 2022), which could link to Schook et al.'s (2015) hypothesis on IOD generation following inflammation induced by obesity. Evidently, experiments with rats that lasted from days to weeks cannot be simply transferred to mechanisms acting over several years in zoo-managed rhinos. Nevertheless, the hypothesis that IOD could be related to general stress susceptibility should be further investigated.

### **Conclusion**

Black rhino husbandry remains challenging. The overwhelming presence of IOD signs clearly warrants further investigation into and proactive management of the disorder. In particular, training rhinos for routine blood sampling and possibly phlebotomy or application of chelators should be a priority in black rhino husbandry.

IOD and the high prevalence of skin conditions and gastric ulceration all emphasise that husbandry measures aimed at reducing stress should be a priority. Providing black rhinos

with seclusion from both conspecifics and humans may be very beneficial. Enclosure elements that facilitate withdrawal, for example curtain-type structures, could be explored in exhibits where animals cannot hide from caretakers.

The high prevalence of IOD, excessive tooth wear, gastric ulcers and other gastrointestinal diseases additionally emphasise the relevance of a species-appropriate feeding regime, which may still be difficult to achieve. For example, it has been suggested that lucerne hay as the main forage source may induce digestive upset (Dierenfeld 1999) or be a major source of dietary iron (Claus et al. 2012) and should therefore be fed restrictively. Yet, with respect to tooth wear and gastric ulcers it represents an optimum forage of choice. Lucerne harvested with specific care (avoiding soil contamination) would already represent progress. Offering a variety of non-grass forage items (i.e. browse and other arable dicots such as sanfoin *Onobrychis viciifolia*) remains a promising yet difficult to achieve approach and may require more decisive action across black rhino facilities. Access to branches (not necessarily with leaves) should be available at all times.

Finally, efforts to investigate black rhino diseases need to continue. This must include routinely taken blood samples from both clinically healthy and diseased animals and detailed, standardised post-mortem investigations that follow a protocol of listing macroscopic and histologic findings for all organs, specifically addressing the presence and absence of peculiar black rhino problems and adrenal indicators of chronic stress.

## Acknowledgments

We thank all participating institutions for the provision of the necropsy reports, as well as Annika Avedik for the photograph of the museum specimen and Emilia Claus for the drawings used in Figure 2.

## References

Ackermans N.L., Winkler D.E., Martin L.F., Kaiser T.M., Claus M., Hatt J.M. (2020) Dust and grit matter: Abrasives of different size lead to opposing dental microwear textures in experimentally fed sheep (*Ovis aries*). *Journal of Experimental Biology* 223(3): jeb.220442. doi:10.1242/jeb.220442

Andrews F.M., Larson C., Harris P. (2017) Nutritional management of gastric ulceration. *Equine Veterinary Education* 29(1): 45–55. doi:10.1111/eve.12495

Barbiers R. (1994) Mycobacterium tuberculosis in a black rhinoceros (*Diceros bicornis*). *Proceedings of the American Association of Zoo Veterinarians* 1994: 149.

Bäuerlein V., Sabban C., Venner M., Vervuert I. (2020) Effects of feeding alfalfa hay in comparison to meadow hay on the gastric mucosa in adult Warmblood horses. *Pferdeheilkunde - Equine Medicine* 36: 29–36. doi:10.21836/PEM20200105

Beagley J.C., Lowder M.C., Langan J.N., Citino S.B. (2010) Dental conditions of captive black rhinoceros (*Diceros bicornis*). *Proceedings of the American Association of Zoo Veterinarians* 2010: 138–139.

Bertsch M., Terranova M., Kreuzer M., Claus M. (2022) Particle size distribution in commercial pig compound feeds in Switzerland: Survey and methodological considerations. *Schweizer Archiv für Tierheilkunde* 164(9): 635–644. doi:10.17236/sat00366

Bryant B., Blyde D., Eamens G., Whittington R. (2012) Mycobacterium avium subspecies paratuberculosis cultured from the feces of a southern black rhinoceros (*Diceros bicornis minor*) with diarrhea and weight loss. *Journal of Zoo and Wildlife Medicine* 43(2): 391–393. doi:10.1638/2010-0161.1

Carlstead K., Brown J.L. (2005) Relationships between patterns of fecal corticoid excretion and behavior, reproduction, and environmental factors in captive black (*Diceros bicornis*) and white (*Ceratotherium simum*) rhinoceros. *Zoo Biology* 24(3): 215–232.

Cersosimo L.M., Sullivan K.E., Valdes E.V. (2022) Species and individual rhinoceros affect the bacterial communities, metabolites, and nutrient composition in faeces from Southern black rhinoceros (*Diceros bicornis minor*) and Southern white rhinoceros (*Ceratotherium simum simum*) under managed care. *Journal of Animal Physiology and Animal Nutrition* 106(1): 181–193. doi:10.1111/jpn.13520

Chaplin Jr. H., Malecek A.C., Miller R.E., Bell C.E., Gray L.S., Hunter V.L. (1986) Acute intravascular hemolytic anemia in the black rhinoceros: Hematologic and immunohematologic observations. *American Journal of Veterinary Research* 47(6): 1313–1320.

Claus M., Polster C., Kienzle E., Wiesner H., Baumgartner K., von Houwald F., Ortmann S., Streich W.J., Dierenfeld E.S. (2005) Studies on digestive physiology and feed digestibilities in captive Indian rhinoceros (*Rhinoceros unicornis*). *Journal of Animal Physiology and Animal Nutrition* 89(3–6): 229–237. doi:10.1111/j.1439-0396.2005.00546.x

Claus M., Hatt J.M. (2006) The feeding of rhinoceros in captivity. *International Zoo Yearbook* 40(1): 197–209. doi:10.1111/j.1748-1090.2006.00197.x

Claus M., Franz-Odenaal T.A., Brasch J., Castell J.C., Kaiser T.M. (2007a) Tooth wear in captive giraffes (*Giraffa camelopardalis*): Mesowear analysis classifies free-ranging specimens as browsers but captive ones as grazers. *Journal of Zoo and Wildlife Medicine* 38(3): 433–445. doi:10.1638/06-032.1

Claus M., Castell J.C., Kienzle E., Schramel P., Dierenfeld E.S., Flach E.J., Behlert O., Streich W.J., Hummel J., Hatt J.M. (2007b) Mineral absorption in the black rhinoceroses (*Diceros bicornis*) as compared with the domestic horse. *Journal of Animal Physiology and Animal Nutrition* 91(5–6): 193–204. doi:10.1111/j.1439-0396.2007.00692.x

Claus M., Dierenfeld E.S. (2008) The nutrition of browsers. In: Fowler M.E., Miller R.E. (eds.). *Zoo and Wild Animal Medicine Current Therapy* 6. St. Louis, Missouri: Saunders Elsevier, 444–454.

Claus M., Dierenfeld E., Goff J., Klasing K., Koutsos L., Lavin S., Livingston S., Nielson B., Schlegel M., Sullivan K., Valdes E., Ward A. (2012) IOD in rhinos – nutrition group report: Report from the Nutrition Working Group of the International Workshop on Iron Overload Disorder in Browsing Rhinoceros (February 2011). *Journal of Zoo and Wildlife Medicine* 43(3): S108–S113. doi:10.1638/1042-7260-43.3s.S108

Claus M., Paglia D.E. (2012) Iron storage disorders in captive wild mammals: The comparative evidence. *Journal of Zoo and Wildlife Medicine* 43(3s): S6–S18. doi:10.1638/2011-0152.1

Dennis P.M. (2004) *Epidemiology of Black Rhinoceroses (Diceros bicornis) in Captivity in the United States*. Ohio State University, PhD Thesis.

Dennis P.M., Funk J.A., Rajala-Schultz P.J., Blumer E.S., Miller R.E., Wittum T.E., Saville W.J.A. (2007) A review of some of the health issues of captive black rhinoceroses (*Diceros bicornis*). *Journal of Zoo and Wildlife Medicine* 38(4): 509–517. doi:10.1638/MS05-012.1

Dierenfeld E.S. (1999) Rhinoceros feeding and nutrition. In: Fowler M.E., Miller R.E. (eds.). *Fowler's Zoo and Wild Animal Medicine IV Current Therapy*. Philadelphia, Pennsylvania: W.B. Saunders.

Dorsey C., Dennis P., Guagnano G., Wood T., Brown J.L. (2010) Decreased baseline fecal glucocorticoid concentrations associated with skin and oral lesions in black rhinoceros (*Diceros bicornis*). *Journal of Zoo and Wildlife Medicine* 41(4): 616–625. doi:10.1638/2009-0162.1

Douglass E.M., Plue R.E. (1980) Hemolytic anemia suggestive of leptospirosis in the black rhinoceros. *Journal of the American Veterinary Medical Association* 177(9): 921–923.

Edwards K.L., Walker S.L., Dunham A.E., Pilgrim M., Okita-Ouma B., Shultz S. (2015) Low birth rates and reproductive skew limit the viability of Europe's captive eastern black rhinoceros, *Diceros bicornis michaeli*. *Biodiversity and Conservation* 24: 2831–2852. doi:10.1007/s10531-015-0976-7

Emslie R., Brooks M. (1999) *African Rhino. Status Survey and Conservation Action Plan*. Gland, Switzerland: IUCN/SSC African Rhino Specialist Group, IUCN.

Emslie R.H. (2013) African Rhinoceroses – Latest Trends in Rhino Numbers and Poaching. An update to Doc 54-2-Annexe 2 from the IUCN Species Survival Commission's (IUCN/SSC), African Rhino Specialist Group to the CITES Secretariat pursuant to Resolution Conf. 9.14, (Rev. CoP15) CITES CoP16 Inf Doc 51. Cambridge, UK: IUCN.

Espie I.W., Hlokwé T.M., van Pittius N.C.G., Lane E., Tordiffe A.S.W., Michel A.L., Müller A., Kotze A., van Helden P.D. (2009) Pulmonary infection due to Mycobacterium bovis in a black rhinoceros (*Diceros bicornis minor*) in South Africa. *Journal of Wildlife Diseases* 45(4): 1187–1193.

Farhadinia M.S., Johnson P.J., Zimmermann A., McGowan P.J.K., Meijaard E., Stanley-Price M., Macdonald D.W. (2020) Ex situ management as insurance against extinction of mammalian megafauna in an uncertain world. *Conservation Biology* 34(4): 988–996. doi:10.1111/cobi.13496

Flood J., Stewart A.J. (2022) Non-steroidal anti-inflammatory drugs and associated toxicities in horses. *Animals* 12(21): 2939.

Fortelius M. (1982) *Ecological aspects of dental functional morphology in the Plio-Pleistocene rhinoceroses of Europe*. In: Kurtén B. (ed.) *Teeth: Form, Function and Evolution*. New York, New York: Columbia University Press, 163–181.



- Fortelius M. (1985) Ungulate cheek teeth: Developmental, functional, and evolutionary interrelations. *Acta Zoologica Fennica* 180: 1–76.
- Galinelli N., Wambacq W., Broeckx B.J.G., Hesta M. (2021) High intake of sugars and starch, low number of meals and low roughage intake are associated with Equine Gastric Ulcer Syndrome in a Belgian cohort. *Journal of Animal Physiology and Animal Nutrition* 105(S2): 18–23.
- Guo S., Yang C., Jiang S., Ni Y., Zhao R., Ma W. (2020) Repeated restraint stress enhances hepatic TFR2 expression and induces hepatic iron accumulation in rats. *Biological Trace Element Research* 196: 590–596. doi:10.1007/s12011-019-01956-4
- He F., Ma L., Wang H., Shen Z., Li M. (2011) Glucocorticoid causes iron accumulation in liver by up-regulating expression of iron regulatory protein 1 gene through GR and STAT5. *Cell Biochemistry and Biophysics* 61: 65–71. doi:10.1007/s12013-011-9162-z
- Helbing M., Terranova M., Kreuzer M., Clauss M. (2022) Evaluation of the prevalence of stomach ulcers in slaughtered pigs in a Swiss abattoir. *Schweizer Archiv für Tierheilkunde* 164(4): 329–338.
- IUCN (2021) *The IUCN Red List of Threatened Species*. Version 2021-3. <https://www.iucnredlist.org>. Accessed on 10 December 2021.
- Janis C.M. (1988) An estimation of tooth volume and hypsodonty indices in ungulate mammals and the correlation of these factors with dietary preferences. In: Russell D.E., Santoro J.P., Signogneau-Russell D. (eds.) *Teeth Revisited Proceedings of the VIth International Symposium on Dental Morphology Mémoires du Muséum national d'Histoire Naturelle, Paris* (series C) 53, 367–387.
- Jarofke D., Klös H.G., Frese R. (1991) Zuchtbuchauswertung der Todesursachen von Spitzmaulnashörnern (*Diceros bicornis*) in zoologischen Gärten. *Verhandlungen Erkrankungen Zootiere* 33: 333–336.
- Jessup D.A., Miller R.E., Bolin C.A., Kock M.D., Morkel P. (1992) Retrospective evaluation of leptospirosis in free-ranging and captive black rhinoceroses (*Diceros bicornis*) by microscopic agglutination titers and fluorescent antibody testing. *Journal of Zoo and Wildlife Medicine* 23(4): 401–408.
- Jiang S., Guo T., Guo S., Gao J., Ni Y., Ma W., Zhao R. (2021) Chronic variable stress induces hepatic Fe(II) deposition by up-regulating ZIP14 expression via miR-181 family pathway in rats. *Biology* 10(7): 653. doi:10.3390/biology10070653
- Kenny D.E., Cambre R.C., Spraker T.R., Stears J.C., Park R.D., Colter S.B., de Lahunta A., Zuba J.R. (1996) Leukoencephalomalacia in a neonatal female black rhinoceros (*Diceros bicornis*): Report of a fourth case. *Journal of Zoo and Wildlife Medicine* 27(2): 259–265.
- Kenny D.E. (1999) Salmonella spp. survey of captive rhinoceroses in U.S. zoological institutions and private ranches. *Journal of Zoo and Wildlife Medicine* 30(3): 383–388.
- Kock N., Foggin C., Kock M.D., Kock R. (1992) Hemosiderosis in the black rhinoceros (*Diceros bicornis*): A comparison of free-ranging and recently captured animals with translocated and captive animals. *Journal of Zoo and Wildlife Medicine* 23(2): 230–234.
- Linklater W.L., MacDonald E.A., Flament J.R.B., Czekala N.M. (2010) Declining and low fecal corticoids are associated with distress, not acclimation to stress, during the translocation of African rhinoceros. *Animal Conservation* 13(1): 104–111. doi:10.1111/j.1469-1795.2009.00308.x
- Lowenstine L.J., Munson L. (1999) Iron overload in the animal kingdom. In: Fowler M.E., Miller R.E. (eds.) *Zoo and Wild Animal Medicine Current Therapy 4*. Philadelphia, Pennsylvania: W.B. Saunders, 260–268.
- Malmkvist J., Poulsen J.M., Luthersson N., Palme R., Christensen J.W., Søndergaard E. (2012) Behaviour and stress responses in horses with gastric ulceration. *Applied Animal Behaviour Science* 142(3–4): 160–167. doi:10.1016/j.applanim.2012.10.002
- Mann P.C., Bush M., Janssen D.L., Frank E.S., Montali R.J. (1981) Clinicopathologic correlations of tuberculosis in large zoo mammals. *Journal of the American Veterinary Medical Association* 179(11): 1123–1129.
- Jurado O.M., Clauss M., Streich W.J., Hatt J.M. (2008) Irregular tooth wear and longevity in captive wild ruminants: A pilot survey of necropsy reports. *Journal of Zoo and Wildlife Medicine* 39(1): 69–75.
- Merceron G., Ramdarshan A., Blondel C., Boisserie J.R., Brunetiere N., Francisco A., Gautier D., Milhet X., Novello A., Pret D. (2016) Untangling the environmental from the dietary: Dust does not matter. *Proceedings of the Royal Society B* 283(1838): 20161032. doi:10.1098/rspb.2016.1032
- Miller R.E., Cambre R.C., de Lahunta A., Brannian R.E., Spraker T.R., Johnson C., Boever W.J. (1990) Encephalomalacia in three black rhinoceroses (*Diceros bicornis*). *Journal of Zoo and Wildlife Medicine* 21(2): 192–199.
- Miller M., Schille B., Pancake C. (2008) Salmonella surveillance in a herd of asymptomatic captive black rhinoceros (*Diceros bicornis*) using fecal culture and PCR. *Journal of Zoo and Wildlife Medicine* 39(1): 56–60. doi:10.1638/2007-0001.1
- Miller M., Michel A., van Helden P., Buss P. (2017) Tuberculosis in rhinoceros: An underrecognized threat? *Transboundary and Emerging Diseases* 64(4): 1071–1078. doi:10.1111/tbed.12489
- Miller M.A., Buss P.E. (2003) Rhinocerotidae (Rhinoceroses). In: Miller R.E., Fowler M.E. (eds.) *Fowler's Zoo and Wild Animal Medicine Volume 5*. St. Louis, Missouri: Saunders Elsevier, 538–547.
- Miller M.A., Buss P.E. (2015) Rhinocerotidae (Rhinoceroses). In: Miller R.E., Fowler M.E. (eds.) *Fowler's Zoo and Wild Animal Medicine Volume 8*. St. Louis, Missouri: Elsevier Saunders, 538–547.
- Miller R.E., Boever W.J. (1982) Fatal hemolytic anemia in the black rhinoceros: Case report and a survey. *Journal of the American Veterinary Medical Association* 181(11): 1228–1231.
- Miller R.E., Bolin C.A. (1988) Evaluation of leptospirosis in black rhinoceroses (*Diceros bicornis*) by microscopic agglutination and fluorescent antibody testing. *Proceedings of the American Association of Zoo Veterinarians* 1988: 161–162.
- Mukinya J.G. (1973) Density, distribution, population structure and social organization of the black rhinoceros in Masai Mara Game Reserve. *African Journal of Ecology* 11(3–4): 385–400. doi:10.1111/j.1365-2028.1973.tb00100.x
- Muneuchi I., Sochi C., Ushio K., Yoshizumi K., Hashimoto W. (2018) The treatment of eastern black rhinoceros suspicious for hyperferreraemia. *Journal of Japanese Association of Zoos and Aquariums* 60(3): 74–83.
- Munson L., Koehler J.W., Wilkinson J.E., Miller R.E. (1998) Vesicular and ulcerative dermatopathy resembling superficial necrolytic dermatitis in captive black rhinoceroses (*Diceros bicornis*). *Veterinary Pathology* 35: 31–42.
- Munson L., Miller R.E. (1999) Skin diseases of black rhinoceroses. In: Fowler M.E., Miller R.E., (eds.) *Fowler's Zoo and Wild Animal Medicine IV Current Therapy*. Philadelphia, Pennsylvania: W.B. Saunders, 551–555.
- Murnane R.D., Raverty S.A., Briggs M., Phillips L.G. (1994) Chronic recurrent anemia, massive pulmonary and systemic mineralization, chronic interstitial nephritis and membranoproliferative glomerulonephritis, and hemosiderosis with myelophthisis in a euthanatized black rhinoceros. *Proceedings of the American Association of Zoo Veterinarians* 1994: 325–331.
- Murray S., Lung N.P., Alvarado T.P., Gamble K.C., Miller M.A., Paglia D.E., Montali R.J. (1999) Idiopathic hemorrhagic vasculopathy syndrome in seven black rhinoceros. *Journal of the American Veterinary Medical Association* 216(2): 230–233.
- Ndeereh D., Okita-Ouma B., Gaymer J., Mutinda M., Gakuya F. (2012) Unusual mortalities of the eastern black rhinoceros (*Diceros bicornis michaeli*) due to clostridial enterotoxaemia in Ol Jogi Pyramid Sanctuary, Kenya. *Pachyderm* 51: 45–51.
- Neiffer D.L., Klein E.C., Wallace-Switalski C. (2001) Leptospira infection in two black rhinoceroses (*Diceros bicornis michaeli*). *Journal of Zoo and Wildlife Medicine* 32(4): 476–486. doi:10.1638/1042-7260(2001)032[0476:LIITBR]2.0.CO;2
- Olias P., Mundhenk L., Bothe M., Ochs A., Gruber A.D., Klopffleisch R. (2012) Iron overload syndrome in the black rhinoceros (*Diceros bicornis*): Microscopical lesions and comparison with other rhinoceros species. *Journal of Comparative Pathology* 147(4): 542–549. doi:10.1016/j.jcpa.2012.07.005
- Paglia D.E. (1993) Acute episodic hemolysis in the African black rhinoceros as an analogue of human glucose-6-phosphate dehydrogenase deficiency. *American Journal of Hematology* 42(1): 36–45. doi:10.1002/ajh.2830420109
- Paglia D.E. (1994) Haemolytic anaemia in captive black rhinoceroses: Potential strategies for prevention and therapy. *Proceedings of a Symposium on "Rhinos as Game Ranch Animals"*: 196–198.
- Paglia D.E., Dennis P. (1999) Role of chronic iron overload in multiple disorders of captive black rhinoceroses (*Diceros bicornis*). *Proceedings of the American Association of Zoo Veterinarians Annual Meeting* 1999: 163–170.
- Paglia D.E., Radcliffe R.W. (2000) Anthracycline cardiotoxicity in a black rhinoceros (*Diceros bicornis*): Evidence for impaired antioxidant capacity compounded by iron overload. *Veterinary Pathology* 37: 86–88.
- Paglia D.E., Kenny D.E., Dierenfeld E.S., Tsu I.H. (2001) Role of excessive maternal iron in the pathogenesis of congenital leukoencephalomalacia in captive black rhinoceroses (*Diceros bicornis*). *American Journal of Veterinary Research* 62(3): 343–349. doi:10.2460/ajvr.2001.62.343

- Paglia D.E., Tsu I.H. (2012) Review of laboratory and necropsy evidence for iron storage disease acquired by browser rhinoceroses. *Journal of Zoo and Wildlife Medicine* 43(3s): S92–S104. doi:10.1638/2011-0177.1
- Pessier A.P., Munson L., Miller R.E. (2004) Oral, nasal, and cutaneous eosinophilic granulomas in the black rhinoceros (*Diceros bicornis*): A lesion distinct from superficial necrolytic dermatitis. *Journal of Zoo and Wildlife Medicine* 35(1): 1–7. doi:10.1638/03-039
- Pilgrim M., Biddle R. (2020) EAZA Best Practice Guidelines Black Rhinoceros (*Diceros bicornis*). Amsterdam, Netherlands: EAZA.
- Pohlin F., Hofmeyr M., Hooijberg E.H., Blackhurst D., Reuben M., Cooper D., Meyer L.C. (2020) Challenges to animal welfare associated with capture and long road transport in boma-adapted black (*Diceros bicornis*) and semi-captive white (*Ceratotherium simum*) rhinoceroses. *Journal of Wildlife Diseases* 56(2): 294–305.
- Portas T.J., Hildebrandt T.B., Bryant B.R., Göritz F., Hermes R. (2010) Seminoma in a southern black rhinoceros (*Diceros bicornis minor*): Diagnosis, surgical management and effect on fertility. *Australian Veterinary Journal* 88(1–2): 57–60. doi:10.1111/j.1751-0813.2009.00532.x
- Pouillevet H., Soetart N., Boucher D., Wedlarski R., Jaillardon L. (2020) Inflammatory and oxidative status in European captive black rhinoceroses: A link with iron overload disorder? *PLoS ONE* 15: e0231514. doi:10.1371/journal.pone.0231514
- R Core Team (2020) *R: A Language and Environment for Statistical Computing*. Version 3.6.3. Vienna, Austria: R Foundation for Statistical Computing. <http://www.R-project.org/>.
- Radcliffe R.W., Paglia D.E., Couto C.G. (2000) Acute lymphoblastic leukemia in a juvenile southern black rhinoceros (*Diceros bicornis minor*). *Journal of Zoo and Wildlife Medicine* 31(1): 71–76. doi:10.1638/1042-7260(2000)031[0071:ALLIAJ]2.0.CO;2
- Roth T.L., Switzer A., Watanabe-Chailland M., Bik E.M., Relman D.A., Romick-Rosendale L.E., Ollberding N.J. (2019) Reduced gut microbiome diversity and metabolome differences in rhinoceros species at risk for iron overload disorder. *Frontiers in Microbiology* 10: 2291. doi:10.3389/fmicb.2019.02291
- Roth T.L., Philpott M., Wojtusik J. (2022) Rhinoceros serum labile plasma iron and associated redox potential: Interspecific variation, sex bias and iron overload disorder disconnect. *Conservation Physiology* 10(1): coac025. doi:10.1093/conphys/coac025
- Sanson G.D., Kerr S., Read J. (2017) Dietary exogenous and endogenous abrasives and tooth wear in African buffalo. *Biosurface and Biotribology* 3(4): 211–223. doi:10.1016/j.bsbt.2017.12.006
- Schook M.W., Wildt D.E., Raghanti M.A., Wolfe B.A., Dennis P.M. (2015) Increased inflammation and decreased insulin sensitivity indicate metabolic disturbances in zoo-managed compared to free-ranging black rhinoceros (*Diceros bicornis*). *General and Comparative Endocrinology* 217–218: 10–19. doi:10.1016/j.ygcn.2015.05.003
- Schulz-Kornas E., Winkler D.E., Clauss M., Carlsson J., Ackermans N.L., Martin L.F., Hummel J., Müller D.W.H., Hatt J.M., Kaiser T.M. (2020) Everything matters: Molar microwear texture in goats (*Capra aegagrus hircus*) fed diets of different abrasiveness. *Palaeogeography, Palaeoclimatology, Palaeoecology* 552: 109783. doi:10.1016/j.palaeo.2020.109783
- Spiers J.G., Tan L.S., Anderson S.T., Hill A.F., Lavidis N.A., Chen H.J.C. (2022) Hepatic homeostasis of metal ions following acute repeated stress exposure in rats. *Antioxidants* 11(1): 85. doi:10.3390/antiox11010085
- Strauss G., Wisser J. (1995) Veterinärmedizinische Aspekte der Nashornhaltung im Tierpark Berlin-Friedrichsfelde. *Verhandlungen Erkrankungen Zootiere* 37: 59–69.
- Sullivan K.E., Mylniczenko N.D., Nelson Jr. S.E., Coffin B., Lavin S.R. (2020) Practical management of iron overload disorder (IOD) in black rhinoceros (BR; *Diceros bicornis*). *Animals* 10(11): 1991. doi:10.3390/ani10111991
- Taugner F., Göltenboth R., Hentschke J. (1995) Beitrag zur Hämolyse bei Spitzmaulnashörnern. *Verhandlungen Erkrankungen Zootiere* 37: 71–77.
- Taylor L.A., Müller D.W.H., Schwitzer C., Kaiser T.M., Codron D., Schulz E., Clauss M. (2014) Tooth wear in captive rhinoceroses (*Diceros*, *Rhinoceros*, *Ceratotherium*: Perissodactyla) differs from that of free-ranging conspecifics. *Contributions to Zoology* 83(2): 107–117.
- Valandikar S.C., Raju R. (1996) Pulmonary tuberculosis in black rhinoceros (*Diceros bicornis*) in Mysore Zoo. *Zoos Print* 11(3): 16–17.
- von Houwald F. (2016) Causes and prevention of foot problems in greater one-horned rhinoceros *Rhinoceros unicornis* in zoological institutions. *International Zoo Yearbook* 50(1): 215–224. doi:10.1111/izy.12116
- von Koenigswald W., Anders U., Engels S., Schultz J.A., Kullmer O. (2013) Jaw movement in fossil mammals: Analysis, description and visualization. *Paläontologische Zeitschrift* 87: 141–159. doi:10.1007/s12542-012-0142-4
- von Koenigswald W. (2018) Specialized wear facets and late ontogeny in mammalian dentitions. *Historical Biology* 30(1–2): 7–29. doi:10.1080/08912963.2016.1256399
- Wack A.N., Miller C.L., Wood C.E., Garner M.M., Haeefe H.J. (2010) Melanocytic neoplasms in a black rhinoceros (*Diceros bicornis*) and an Indian rhinoceros (*Rhinoceros unicornis*). *Journal of Zoo and Wildlife Medicine* 41(1): 95–103. doi:10.1638/2009-0085.1
- Weber M., Miller R.E. (1996) Fungal pneumonia in black rhinoceros. *Proceedings of the American Association of Zoo Veterinarians* 1996: 34–36.
- Winkler D.E., Schulz-Kornas E., Kaiser T.M., De Cuyper A., Clauss M., Tütken T. (2019) Forage silica and water content control dental surface texture in guinea pigs and provide implications for dietary reconstruction. *PNAS* 116(4): 1325–1330. doi:10.1073/pnas.1814081116
- Wojtusik J., Roth T.L. (2018) Investigation of factors potentially associated with serum ferritin concentrations in the black rhinoceros (*Diceros bicornis*) using a validated rhinoceros-specific assay. *Journal of Zoo and Wildlife Medicine* 49(2): 297–306. doi:10.1638/2017-0131.1
- Wojtusik J., Curry E., Roth T.L. (2021) Rhinoceros serum microRNAs: Identification, characterization, and evaluation of potential iron overload biomarkers. *Frontiers in Veterinary Science* 8: 711576. doi:10.3389/fvets.2021.711576
- Zhao M., Liu L.J., Li X.G., Wang W.Y., Wang L., Ma L., Shen H., Zhu Z.W., Li M. (2014) Psychological stress leads to hepatic iron accumulation and disturbs iron homeostasis. *Journal of Chemical and Pharmaceutical Research* 6: 1128–1134.