

Research article

## Causes of mortality in sloth bears (*Melursus ursinus*) housed in U.S.

### ZOOS

Kadie M. Anderson<sup>1</sup>, Michael M. Garner<sup>2</sup>, Patricia M. Dennis<sup>1</sup>

<sup>1</sup>Cleveland Metroparks Zoo, 4200 Wildlife Way, Cleveland, OH, 44109, USA

<sup>2</sup>Northwest ZooPath, 654 West Main, Monroe, WA, 98272 USA

Correspondance: Kadie Anderson; wyldvet@gmail.com; (253) 448-5015

**Keywords:** biliary adenocarcinoma, disease, *Melursus ursinus*, mortality, sloth bear

**Article history:**

Received: 06 Sept 2016

Accepted: 17 Oct 2017

Published online: 31 Jan 2018

**Abstract**

A retrospective mortality review was performed of necropsy records from 1905–2015 to determine the mortality trends for the captive U.S. sloth bear (*Melursus ursinus*) population. Records were obtained for 68 bears from 15 institutions. Neonates had an average age at death of 7 days (median 0 days). Neonatal mortality accounted for a significant proportion of reviewed cases (29.4%) and was most often due to stillbirth and infectious disease. Juvenile mortality was uncommon (2.9%). The mean age at death for adult bears was 16.7 years. Biliary adenocarcinoma was the leading cause of death for adult bears (58.7–65.2%) with no apparent gender predilection. Possible causative factors for the high frequency of biliary adenocarcinoma in sloth bears are proposed and compared to other species including humans.

### Introduction

The sloth bear, *Melursus ursinus*, is listed as vulnerable by the IUCN and has been exhibited in U.S. zoos since the late 1800s (Vineyard 2013). As of 2013, there were only 38 sloth bears found in Association of Zoos and Aquarium (AZA) institutions, with nine animals held by a private breeder. A recent viability assessment for the AZA population suggests that projected zoo and aquarium sloth bear numbers will decline to only 20 animals in approximately 16 years due to a low birthing rate (~2 births/year), an aging population, and difficulty in importing new animals into the population (Marti et al. 2012).

While sloth bears have been kept in captive conditions for over a century, mortality trends have not yet been published. Mortality trends serve to inform population managers and veterinarians how best to manage and care for a species, particularly if disease trends are identified. The study aimed to determine whether disease trends were present in the population.

### Methods

Necropsy and histopathology reports from sloth bears from multiple U.S. institutions were reviewed for the time period of 1905–2015. With the exception of four cases, all reported mortalities fell within the 1970–2015 range (Figure 1). Eighteen AZA sloth bear holding facilities were invited to participate, and 15 institutions participated in the study. Participating zoos included Woodland Park Zoo (n=5), Cleveland Metroparks Zoo (n=1), Capron Park Zoo (n=2), Brookfield Park Zoo (n=4), Little Rock Zoo (n=20), Akron Zoo (n=1), Tautphaus Park Zoo (n=2), Cincinnati Zoo & Botanical Garden (n=6), San Diego Zoo (n=4), Sacramento Zoo (n=3), Philadelphia Zoo (n=9), St Louis Zoo (n=2), Oklahoma City Zoo and Botanical Garden (n=5), Tampa's Lowry Park Zoo (n=3), and Toledo Zoo (n=1). Cause of death and ancillary lesions were documented for each case, and age and gender were included when provided (8 animals had an unknown gender).

The sloth bear studbook was reviewed over a shorter

time period (1970–2015) to determine what percentage of the population was represented by the data. From 1970–2015, 159 mortalities were documented (Vineyard 2013). After removing bears that were unlikely to have a complete necropsy (animals housed in foreign institutions or by private holders and cubs with unknown gender, often reflecting a lack of necropsy), the estimated number of mortalities was 126 animals. Using veterinary and studbook records, two additional neonatal cub mortalities were identified, which bolstered the number of mortalities during this time period to 128 animals. From 1970–2015, the entire AZA sloth bear population (living and deceased) was 220 individuals (Vineyard 2013). A total of 68 reports were available for review which described the death of 28 females, 32 males, and eight neonates of unknown gender. Twenty were neonates (0–30 days), two were juveniles (30 days–3 years) and 46 were adults. Available reports were estimated to represent approximately 53% (68/128) of mortalities during the study period. Multiple pathologists reviewed submitted tissue samples for diagnosis and in some cases, only gross necropsy findings were available.

## Results

Neonatal mortality accounted for 29.4% of reviewed cases (20 of 68). The mean age at neonatal death was 7 days, with the median age at death 0 days. The primary causes of death for neonates were stillbirth (30%, 6 of 20) and infections (30%, 6 of 20), followed by maternal neglect (15%, 3 of 20), trauma (15%, 3 of 20), and unknown causes (10%, 2 of 20). The oldest cub available for review was 29 days of age at time of death and death was attributed to septicemia. The primary causes of death and mean age at death for all age classes are summarised in Table 1.

Mortality during the juvenile stage was uncommon (2.9%, 2 of 68). Only two juvenile animals were represented; a 3 year old male died of purulent bronchopneumonia and a 1 year old female presumably drowned.

The remaining cases were adult animals (>3 years, n=46). The mean age at death was 16.7 years (median = 15.8 years), with the oldest animal surviving to 36.3 years. Female bears lived 17.9 years on average, compared to male bears which lived to 15.5 years. The most common cause of death in adult sloth bears

was biliary adenocarcinoma (BACA; 58.7%, 27 of 46). There were three cases where mortality was attributed to hepatic masses/neoplasia, and if included as possible BACAs, would increase the prevalence to 65.2% (30 of 46). The mean age at death for bears with biliary adenocarcinoma was 17.6 years, with a range of 7–29.5 years. Males and females were equally represented (n=15 and 15, respectively).

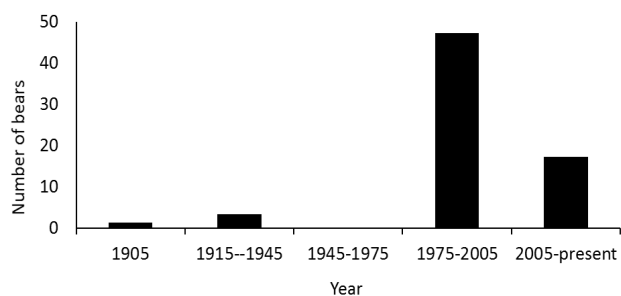
Fatal diseases in adults involving the gastrointestinal tract (n=7) included gastroenteritis/enteritis/gastritis (n=2), rectal prolapse with peritonitis (n=1), *Salmonella enteritis* (n=1), and a colonic mango pit obstruction (n=1). Scirrhus adenocarcinoma of the gastrointestinal tract was identified as the cause of death in two animals. Other causes of death included (n=1 of each), nephritis, a lumbar vertebral mass and discospondylitis (gross only), congestive heart failure (gross only), cutaneous hemangiosarcoma with metastasis to the lungs, bronchopneumonia, spinal trauma, euthanasia for osteoarthritis with pancreatic insufficiency, and suspected pulmonary tuberculosis (gross only). Bears that died of causes other than BACA had an average age at death of 14.8 years (median 12.9 years, n=17).

For all age groups of sloth bears, ancillary gastrointestinal lesions had an overall prevalence of 52.9% (36 of 68). When considering only adult and juvenile bears, there was a 70.8% prevalence of ancillary gastrointestinal lesions (34 of 48). Intestinal lesions were found concurrent with 43.3% (13 of 27) of BACA cases. Lesions associated with BACA included lymphoplasmacytic and eosinophilic enterocolitis (n=3), pyloric/gastric ulcers (n=2), petechial hemorrhage of the intestinal serosal surface (n=2), and one each of esophagitis/gastritis, hyperplasia and dilation of Brunner's glands, serosal fibrosis and neovascularization, mild gastroenteritis, a pancreatic adenocarcinoma, and a pyloric leiomyoma. In a few bears (16.7%, 5 of 27) that succumbed to BACA, secondary neoplastic processes were detected and included pheochromocytoma (n=1), pulmonary bronchoalveolar adenocarcinoma (n=1), salivary gland adenoma, pyloric leiomyoma (n=1) and pancreatic adenocarcinoma (n=1; same as described above).

Of nine animals with identifiable pancreatic lesions, five were concurrent with a BACA (16.7%, 5 of 30). Some animals had more than one pancreatic lesion, which included multifocal fibrosis

**Table 1:** Primary cause of death in sloth bears (*Melursus ursinus*) by age group and mean age at death

Age group	Primary cause of death	Prevalence	Mean age of death
Neonates (0-30 days)	1. Stillbirth	30% (n=6)	7 days (median 0 days) (n=20)
	2. Infections	30% (n=6)	
	3. Maternal neglect and trauma	15% each (n=3 of each)	
Juveniles (30 days-3 years)			
Adults (>3years)	1. Biliary adenocarcinoma	58.7-65.2% (n=27-30)	16.7 years (median 15.8 years)
	2. Gastrointestinal disease	15.2% (n=7)	



**Figure 1.** Sloth bear deaths by year

with atrophy (n=4), chronic interstitial pancreatitis (n=1), ductular hyperplasia (n=2), isolated pancreatic islets (n=1), cyst formation (n=1), pancreatic adenocarcinoma (n=1), and interstitial fibrosis with neoplastic (BACA) invasion (n=1). Ancillary cardiac and cardiovascular lesions were also frequently identified (n=10), with some animals exhibiting multiple lesions, and included interstitial fibrosis (n=6), atherosclerosis or arteriosclerosis (n=4), endocardiosis (n=2), myocardial necrosis (n=1), flaccid heart musculature (n=1), and right ventricular dilatation (n=1).

## Discussion

BACA has been previously reported as a cause of mortality in captive sloth bears (Dorn 1964, Gosselin and Kramer 1984, Kingston and Wright 1985, Montali et al. 1981). In this retrospective mortality report, confirmed or suspected BACA was the primary cause of death in 65.2% of adult sloth bears. Gastrointestinal diseases were the second most common cause of death in 15.2% of adult animals. Neonatal mortality accounted for 29.2% of all submitted cases, and is considered a significant concern for the long-term sustainability of the captive population, which currently produces ~2 cubs/year (Marti et al. 2012).

BACA has been reported in dogs, cats, cattle, sheep, horses, goats, and non-domestic species (Cullen and Popp 2002, Sakai et al. 2015, McClure et al. 1977). In the domestic dog (*Canis lupus familiaris*), BACA is less common than hepatocellular carcinoma and more malignant (87.5% metastasize; Patnaik et al. 1981). In sloth bears, the same appears to be true, with 86.2% of the necropsy reports documenting widespread carcinomatosis and/or metastasis. BACAs have been reported as uncommon tumours in both human and veterinary patients, with this neoplasm representing only 0.36% of all neoplasms reported in a veterinary teaching hospital (Strafuss 1976). In veterinary medicine, they are likely underreported from facilities where they are most likely diagnosed, such as reference laboratories and diagnostic services (Garner M, unpublished data). In human and veterinary patients, clinical symptoms and signs are non-specific, and the tumours are frequently detected during ultrasonography or exploratory surgery, and often, when identified, the disease is advanced (Cullen and Popp 2002, Misra et al. 2003). In veterinary patients, clinical chemistry values often indicate nonspecific hepatic damage. Alpha fetoprotein and bile acids have been reported to be elevated in dogs with hepatic neoplasia but do not differentiate BACA from hepatocellular carcinoma (Center et al. 1985, Lowseth et al. 1991). Ten to 40% of dogs and cats exhibit jaundice, which is less common in human patients (Cullen and Popp 2002, Misra et al. 2003). Prognosis for humans with biliary carcinoma is poor, with a 5 year survival rate reported at 0–10% (Misra et al. 2003). Survival time in veterinary patients has not been reported. In sloth bears, disease is also frequently detected in the latter stages of the disease after metastasis has occurred. To the authors' knowledge, chemotherapeutic or surgical management of this neoplasm in sloth bears has not been attempted.

In 16.7% of the cases, BACA was found concurrent with another neoplastic process with no apparent trend in type of neoplasm. Despite this, three out of five associated neoplastic lesions were associated with the gastrointestinal tract (salivary, pancreatic, gastric) and an additional two bears died of scirrhous intestinal adenocarcinoma. Bears that died of BACA frequently had ancillary gastrointestinal lesions, which may be secondary to physiologic stress or possibly linked to the etiology of this disease (e.g. underlying chronic gastrointestinal inflammation). When hepatic lesions were excluded, pancreatic and intestinal lesions were the most common concurrent lesion. Four out of five bears with pancreatic lesions and BACA had pancreatic fibrosis. The prevalence of pancreatic fibrosis may be due to chronic

gastrointestinal inflammation or a direct result of expansion of the BACA. Bears dying of BACA tended to be older at time of death than those that did not, although a few younger bears did develop the neoplasm.

BACA has been well studied in humans but not in veterinary patients. In humans, multiple risk factors have been proposed including cholelithiasis, enteric disease, clonorchiasis, gender and reproductive history (high parity, young age at first birth, late menarche), obesity, genetics, inflammatory bowel disease, non-alcoholic liver disease, smoking, hepatitis C virus, and diet (Chou and Chan 1976, Hsing et al. 2007, Huai et al. 2014, Lazcano-Ponce et al. 2001, Misra et al. 2003, Welzel et al. 2007). BACA is usually detected in dog and cats aged >10 years (Cullen and Popp 2002). In one domestic dog study, BACAs were not associated with cholelithiasis or gender for intact dogs; however, spayed females had a higher prevalence than intact females (Hayes et al. 1983). Hookworm and whipworm infections were found to be associated with BACA in the same study (Hayes et al. 1983). In domestic cats, female gender has also been associated with this neoplasm (Cullen and Popp 2002).

The causative factors for this disease in sloth bears remain unclear. Cholelithiasis was reported in only one sloth bear which did not die of BACA. In the current study, there was no gender predisposition for the development of BACA in sloth bears. Captive bears are frequently obese due to diet and inactivity (Bourne et al. 2010). Primary infectious hepatic disease was not identified in any bears in this study, but infections with canine adenovirus-1 have been previously reported as causes of morbidity and mortality in the American black bear (*Ursus americanus*), European brown bear (*Ursus arctos arctos*) and Malayan sun bear (*Helarctos malayanus*; Collins et al. 1984, Goodnight and Emanuelson 2012, Kritsepi et al. 1996, Pursell et al. 1983). Enteric disease was a common finding, either as a cause of mortality or as a concurrent lesion. Additionally, intestinal parasitism is a frequent finding in captive bears and may contribute to gastrointestinal inflammation (Bourne et al. 2010). The role of genetics in the development of this disease in sloth bears is unknown.

Dietary factors have been implicated in the development of BACA in humans and may contribute to the development of BACA in sloth bears (Arnhold et al. 1995). In one study, dietary fat was reported as "considerable" in captive sloth bear diets (Arnhold et al. 1995). Wild sloth bear diets contain propolis and formic acid, components which have exhibited anti-carcinogenic properties in laboratory animals (Arnhold et al. 1995). Wild sloth bear diets vary seasonally, but consist primarily of insects (ants and termites) and fruit/plant matter. The component of dietary fruit can be as high as 56% with reported ingestion of insects reaching up to 98.4% of the diet in the non-fruiting season (Joshi et al. 1997, Yogan and et al. 2005). In many zoos, sloth bears are fed diets consisting of fruits and vegetables with pelleted concentrates, such as commercial dog food. Some institutions also feed varying amounts of bread, meat, eggs, chicken, or fish. Published dietary requirements for sloth bears are unavailable and precludes an in-depth dietary evaluation or recommendation for captive sloth bears.

Neonatal mortality is a concern for the long-term sustainability of the captive sloth bear population. The captive sloth bear population has a low reproductive rate (2 cubs/year), underscoring the importance of losses in the neonatal period (Marti et al. 2012). In the current study, neonatal mortality was frequently due to infectious disease or stillbirth. In many instances, cubs were reported as stillborn and histologic exam was not completed. Infectious causes of death included possible viral and bacterial pathogens, but pathogen identification was not reported in any cases. In most cases, bronchopneumonia or interstitial pneumonia were reported. Maternal neglect and trauma were the next most common cause of neonatal mortality, and may reflect unmet

husbandry needs or behavioural issues.

In this retrospective mortality review, BACA was the leading cause of death for adult sloth bears housed in U.S. zoological institutions. The cause for this high prevalence is unclear and warrants additional investigation. Inflammatory lesions in the pancreas and gastrointestinal tract were common concurrent disease processes. Neonatal mortality accounted for nearly 30% of fatalities, with most cubs either stillborn or succumbing to infectious disease. Further research on the appropriate husbandry and diet of captive sloth bears may increase longevity and breeding potential, and improve neonatal survival.

### Acknowledgements

The authors would like to thank SSP coordinators Travis Vineyard and Debbie Thompson for their assistance with data collection.

### References

- Arnhold W., Schrauzer G.N., Heuschele W.P. (1995) Possible dietary influence on hepatobiliary cancer in sloth bears (*Melursus ursinus*). In: *Proceedings of the 1st Annual Conference of the Nutrition Advisory Group (NAG) of the American Zoo and Aquarium Association (AZA)*, Toronto, Ontario, Canada: 135.
- Bourne D.C., Cracknell J.M., Bacon H.J. (2010) Veterinary issues related to bears (Ursidae). *International Zoo Yearbook* 44: 16–32.
- Center S.A., Baldwin B.H., Erb H.N., Tennant B.C. (1985) Bile acid concentrations in the diagnosis of hepatobiliary disease in the dog. *Journal of the American Veterinary Medical Association* 187: 935–940.
- Chou S.T., Chan C.W. (1976) Mucin-producing cholangiocarcinoma: An autopsy study in Hong Kong. *Pathology* 8(4): 321–328.
- Collins J.E., Johnson L.P., Nelson D., Peden W., Boswell R., Draayer H. (1984) Epizootic of adenovirus infection in American black bears. *Journal of the American Veterinary Medical Association* 185: 1430–1432.
- Cullen J.M., Popp J.A. (2002) Tumors of the liver and gall bladder. In: *Tumors in domestic animals*. Meuten D.J. (eds). Ames (IA): Iowa State Press, 483–508.
- Dorn C.R. (1964) Biliary and hepatic carcinomas in bears at the San Diego Zoological Gardens. *Nature* 202: 513–514.
- Goodnight A.L., Emanuelson K. (2012) Two cases of canine adenovirus type 1 infection in Malayan sunbears (*Helarctos malayanus*) at the Oakland Zoo, California. *Proceedings of the American Association of Zoo Veterinarians* 77.
- Gosselin S.J., Kramer L.W. (1984) Extrahepatic biliary carcinoma in sloth bears. *Journal of the American Veterinary Medical Association* 185(11): 1314–1316.
- Hayes Jr H.M., Morin M.M., Rubenstein D.A. (1983) Canine biliary carcinoma: epidemiological comparisons with man. *Journal of Comparative Pathology* 93: 99–107.
- Hsing A.W., Gao Y.-T., Han T.-Q., Rashid A., Sakoda L.C., Wang B.-S., Shen M.-C., Zhang B.-H., Chen J., Fraumeni Jr J.F. (2007) Gallstones and the risk of biliary tract cancer: a population study in China. *British Journal of Cancer* 97: 1577–1582.
- Huai J.-P., Ding J., Ye X.-H., Chen Y.-P. (2014) Inflammatory bowel disease and risk of cholangiocarcinoma: evidence from a meta-analysis of population-based studies. *Asian Pacific Journal of Cancer Prevention* 15(8): 3477–3482.
- Joshi A.R., Garshelis D.L., Smith J.L.D. (1997) Seasonal and habitat-related diets of sloth bears in Nepal. *Journal of Mammals* 78(2): 584–597.
- Kingston R.S., Wright F.H. (1985) Bile duct carcinoma with widespread metastases in a sloth bear. *Journal of Zoo and Wildlife Medicine* 16(1): 16–20.
- Kritsepi M., Rallis T., Psychas V., Tontis D., Leontides S. (1996) Hepatitis in a European brown bear with canine infectious hepatitis-like lesions. *Veterinary Record* 139: 600–601.
- Lazcano-Ponce, E.C., Miquel J.F., Muñoz N., Herrero R., Ferrecio C., Wistuba I.I., de Ruiz P.A., Urista G.A., Nervi F. (2001) Epidemiology and molecular pathology of gallbladder cancer. *CA Cancer Journal for Clinicians* 51: 349–364.
- Lowseth L.A., Gillett, N.A., Chang I.Y., Muggenberg B.A., Boecker B.B. (1991) Detection of serum alpha-fetoprotein in dogs with hepatic tumors. *Journal of the American Veterinary Medical Association* 199: 735–741.
- Marti K., Theis M., Thompson D., Vineyard T. (2012) *Sloth bear (Melursus ursinus) AZA Animal Program Population Viability Analysis Report*. Lincoln Park Zoo, Chicago, IL.
- McClure H.M., Chang J., Golarz M.N. (1977) Cholangiocarcinoma in a margay (*Felis wiedii*). *Veterinary Pathology* 14: 510–512.
- Misra S., Chaturvedi A., Misra N.C., Sharma I.D. (2003) Carcinoma of the gallbladder. *Lancet Oncology* 4: 167–176.
- Montali R.J., Hoopes P.J., Bush M. (1981) Extrahepatic biliary carcinomas in Asiatic bears. *Journal of the National Cancer Institute* 66(3): 603–608.
- Patnaik A.K., Hurvitz A.I., Lieberman P.H., Johnson G.F. (1981) Canine bile duct carcinoma. *Veterinary Pathology* 18: 439–444.
- Pursell A.R., Stuart B.P., Styer E., Case J.L. (1983) Isolation of an adenovirus from black bear cubs. *Journal of Wildlife Diseases* 19: 269–271.
- Sakai H., Yanai T., Yonemaru K., Hirata A., Masegi T. (2015) Gallbladder adenocarcinomas in two captive African lions (*Panthera leo*). *Journal of Zoo and Wildlife Medicine* 34(3): 302–306.
- Strafuss A.C. (1976) Bile duct carcinoma in dogs. *Journal of the American Veterinary Medical Association* 169: 429.
- Vineyard T. (2013) *North American regional studbook, Sloth bear (Melursus ursinus)*. Cleveland Metroparks Zoo, Cleveland, OH, 1–20.
- Welzel T.M., Graubard B.I., El-Serag H.B., Shaib Y.H., Hsing A.W., Davila J.A., McGlynn K.A. (2007) Risk factors for intra- and extrahepatic cholangiocarcinoma in the United States: a population based case-control study. *Clinical Gastroenterology and Hepatology* 5(10): 1221–1228.
- Yoganand K., Rice C.G., Johnsingh A.J.T. (2005) *Evaluating Panna National Park with special reference to ecology of sloth bear (Melursus ursinus)*. Dehradun, Uttarakhand (India): Final project report, Wildlife Institute of India.